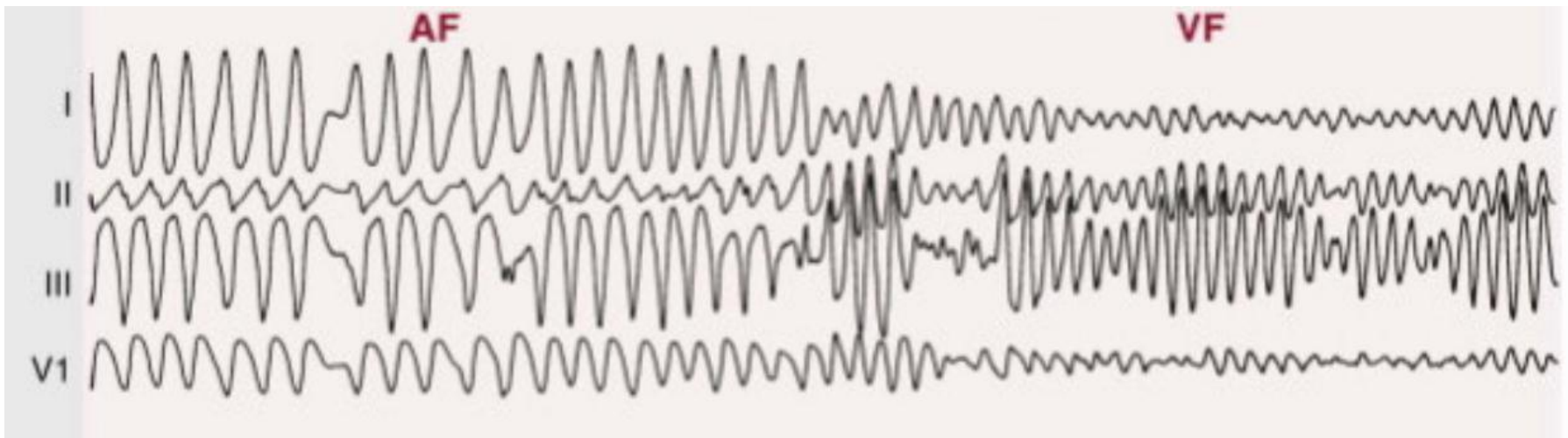


Arritmias (taqui-bradiarritmias)

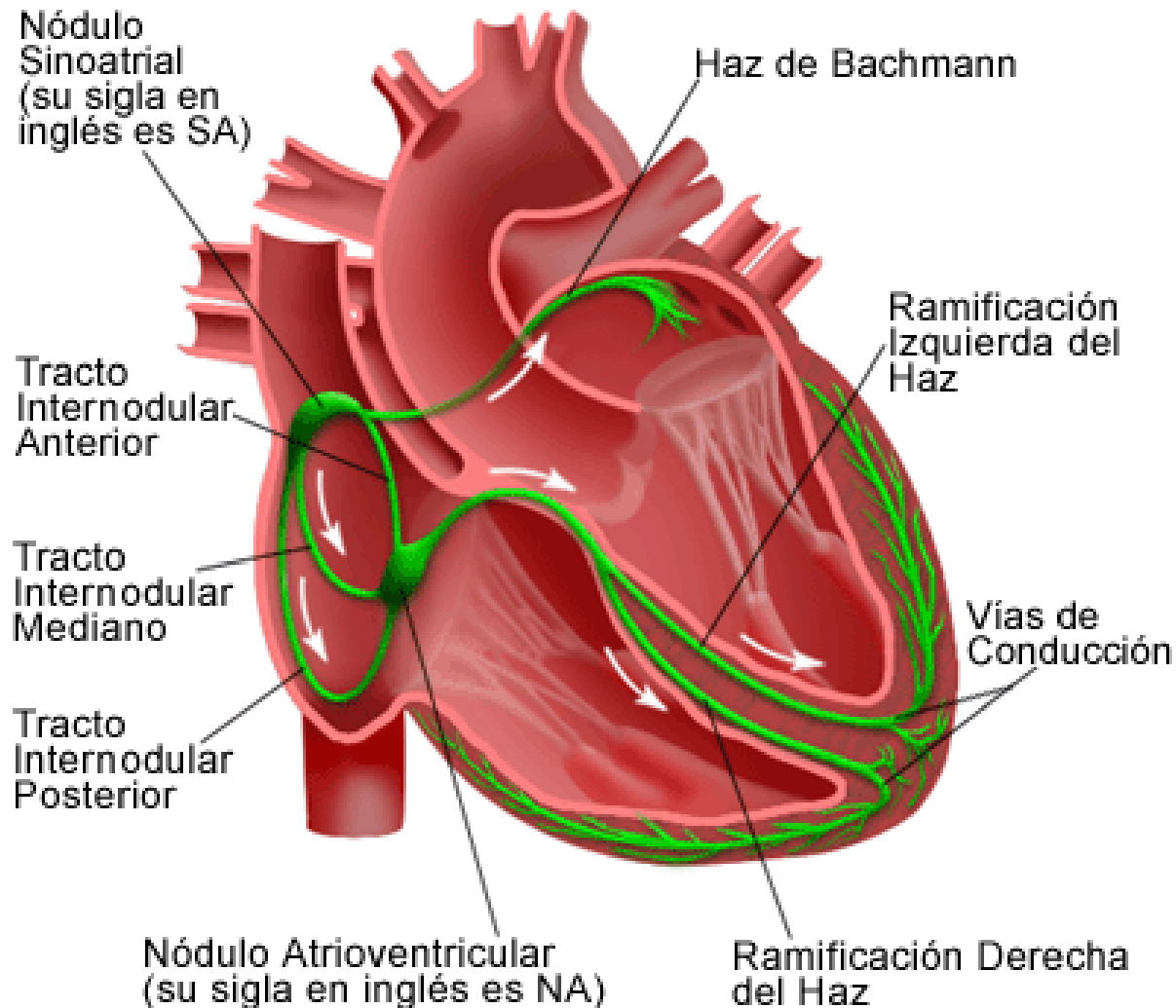


Dra. Chirife, Josefina


Conducción normal








El Sistema Eléctrico del Corazón



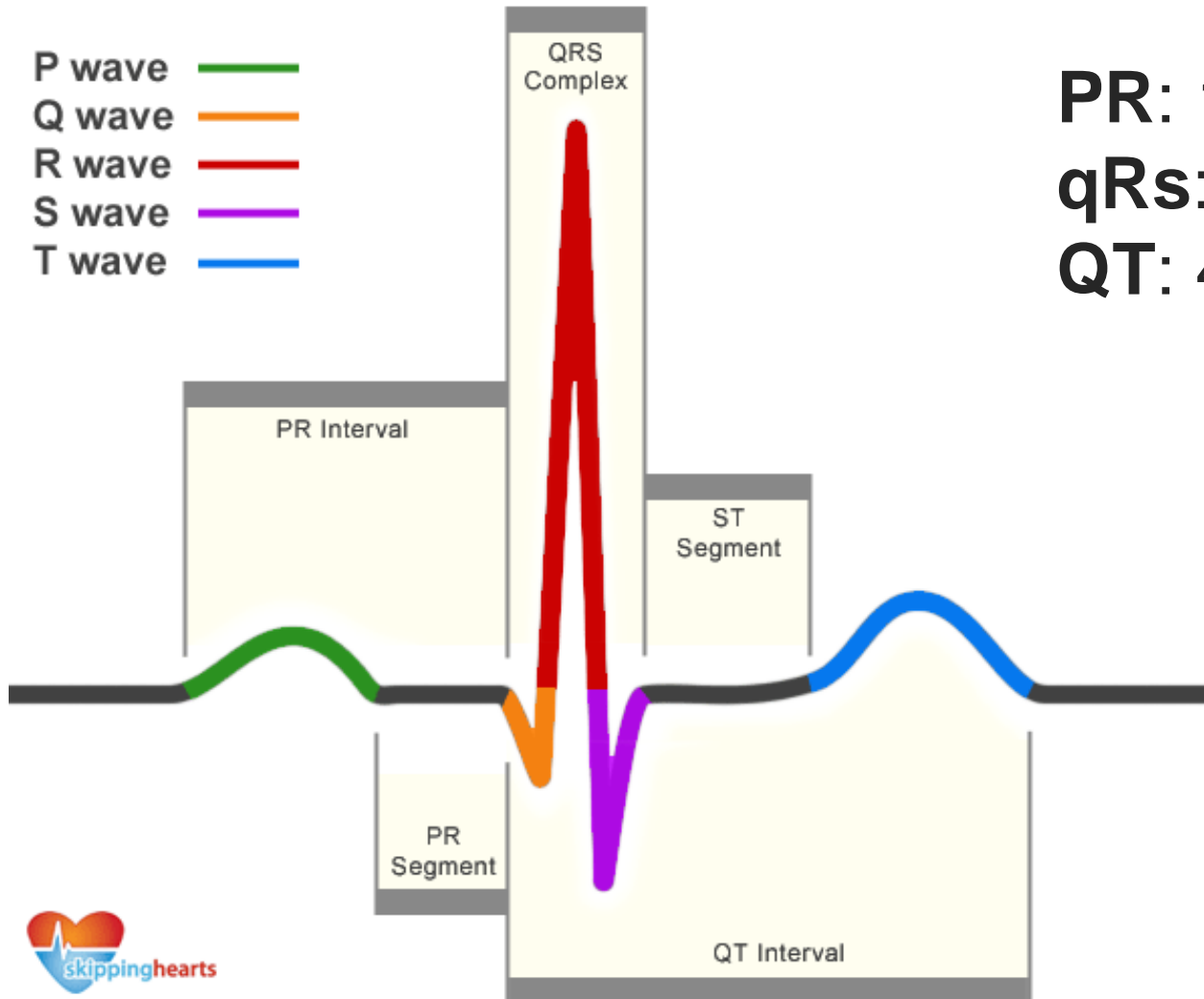
Conducción normal



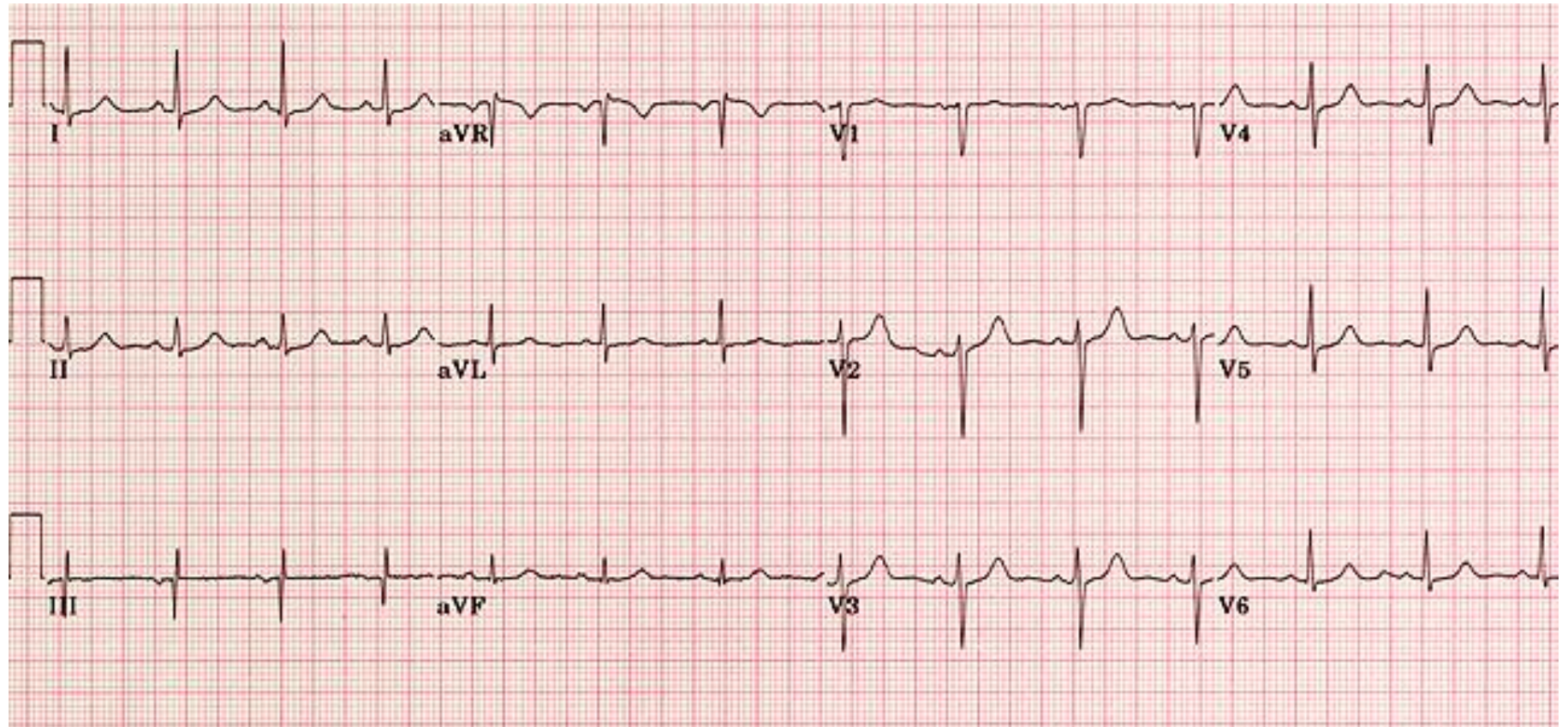

ECG of Normal Sinus Rhythm

- P wave 
- Q wave 
- R wave 
- S wave 
- T wave 

PR: 120-200 ms
qRs: 120 ms
QT: 440 ms




Conducción normal



ECG: RS. FC 95lpm, PR160ms, AqRs +30°.

Mecanismos de las arritmias




Trastornos de
la formación
del impulso

Automatismo (normal/ anormal)

Actividad desencadenada
(PDP/PDT)

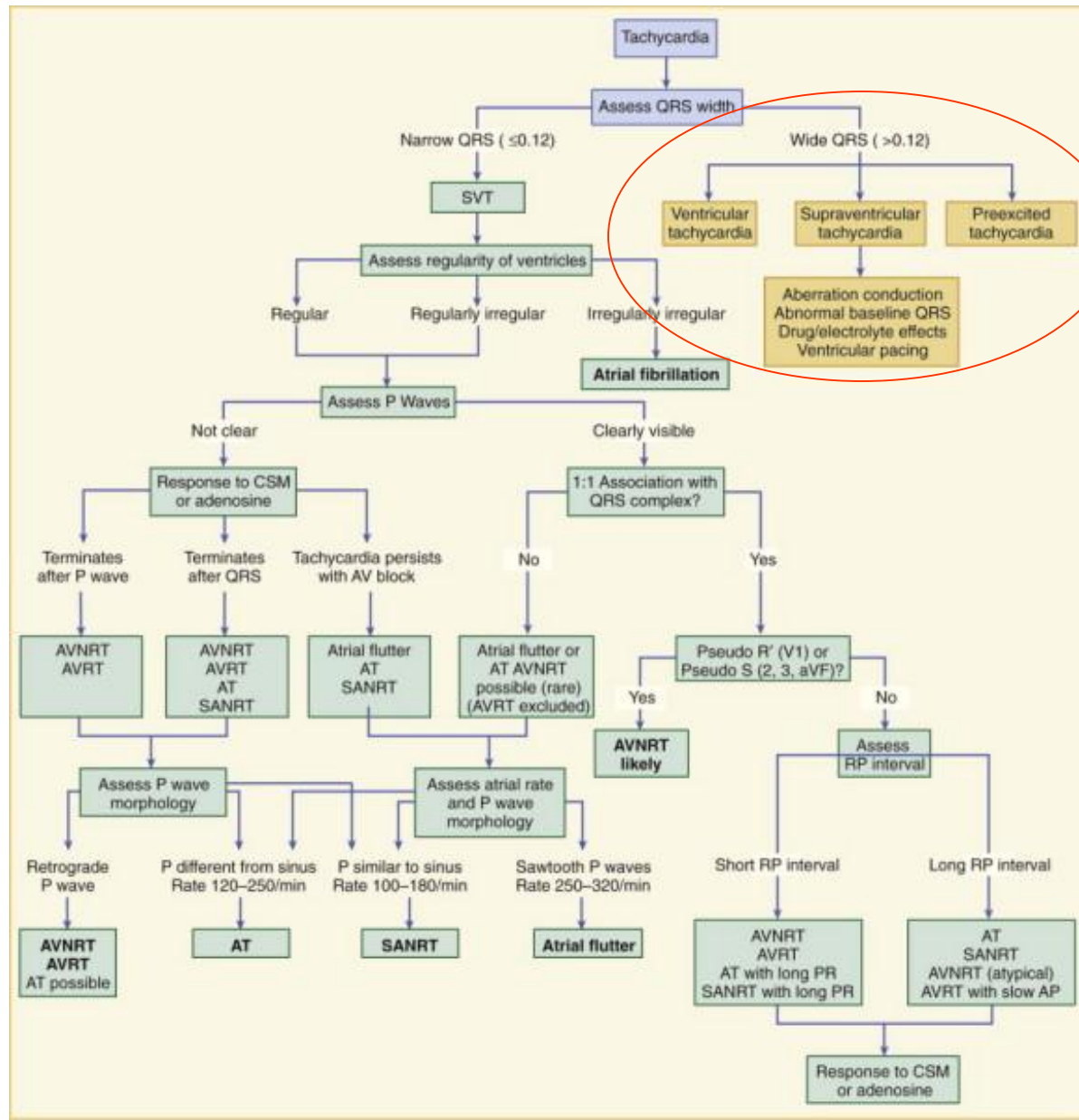

Trastornos de
la conducción
del impulso

Reentrada (anatómica/funcional)

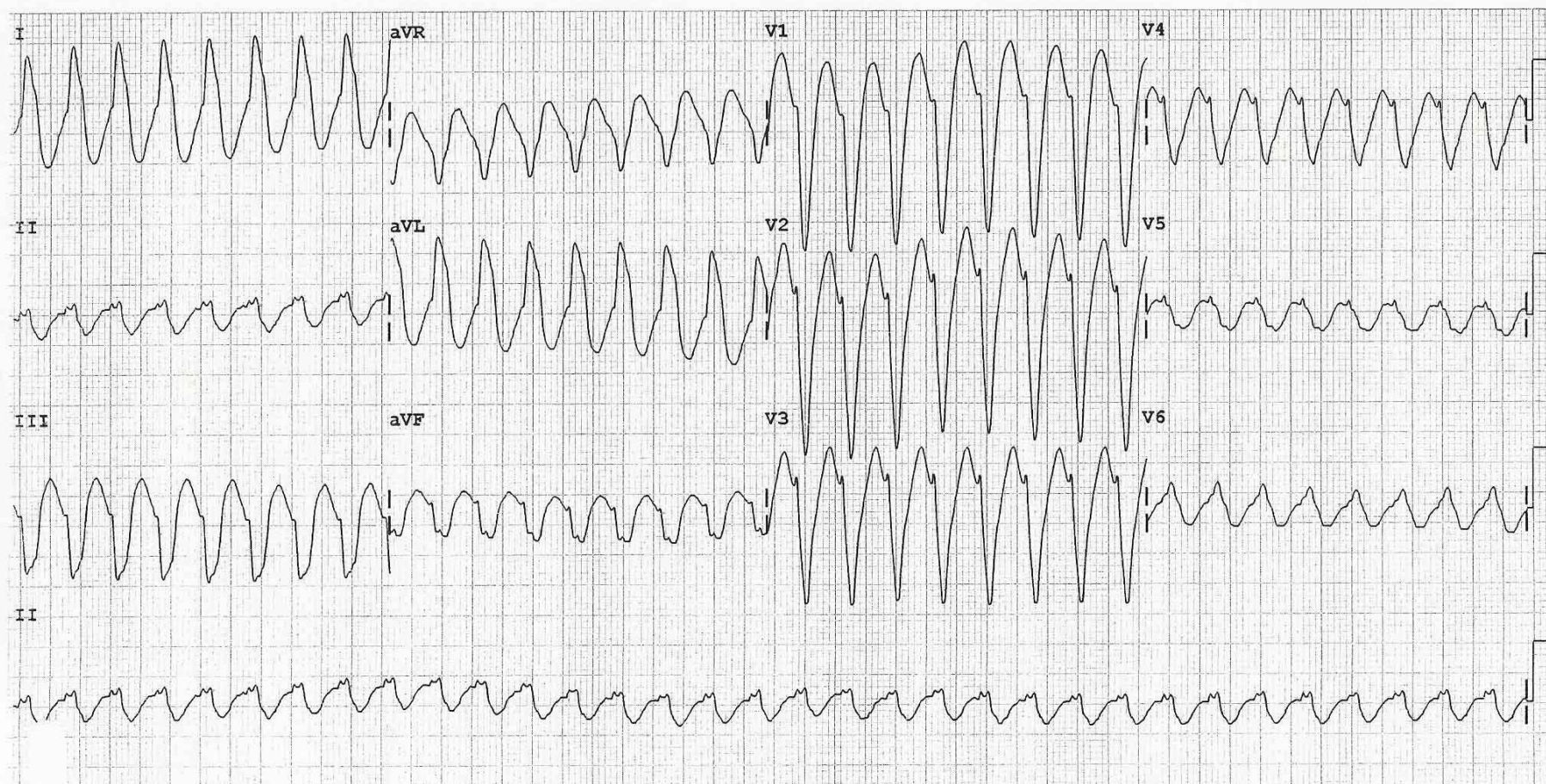



TAQUIARRITMIAS


Taquiarritmias



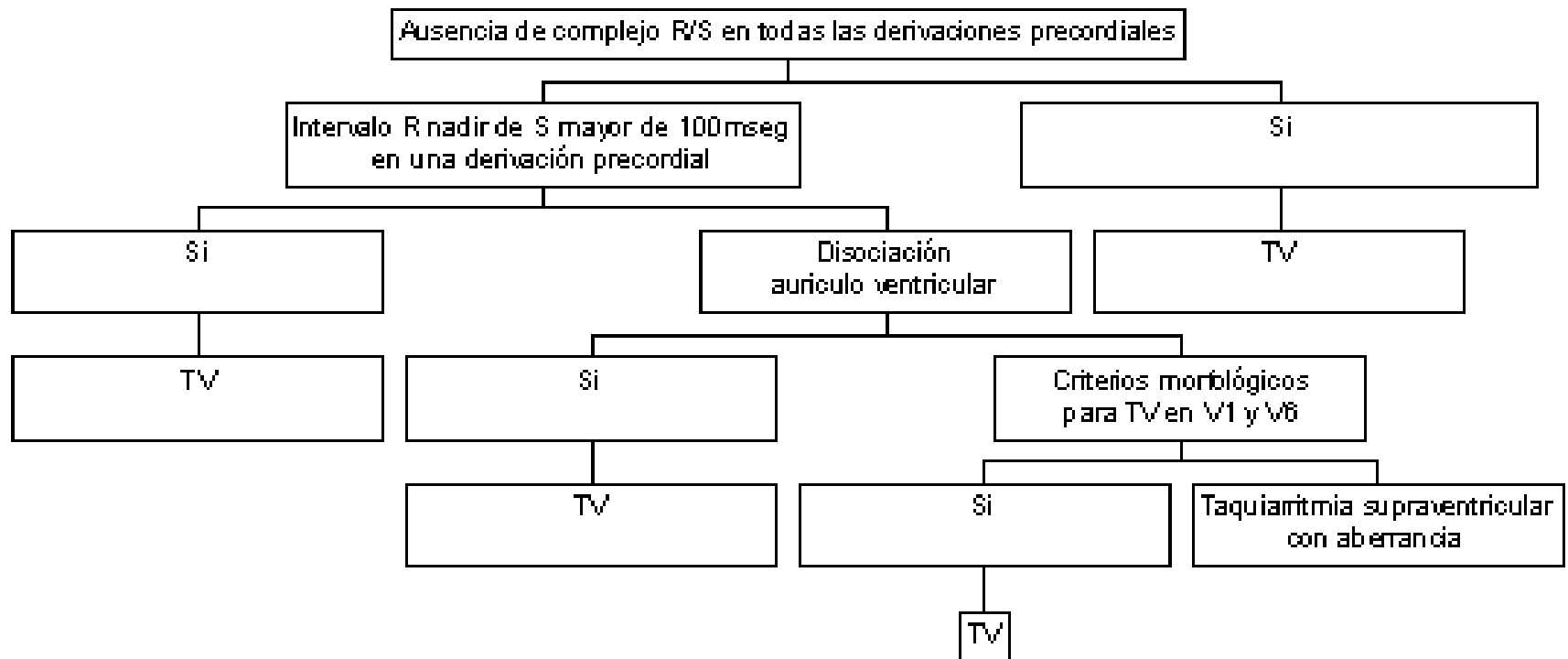
Taquiarritmias




Taquiarritmias



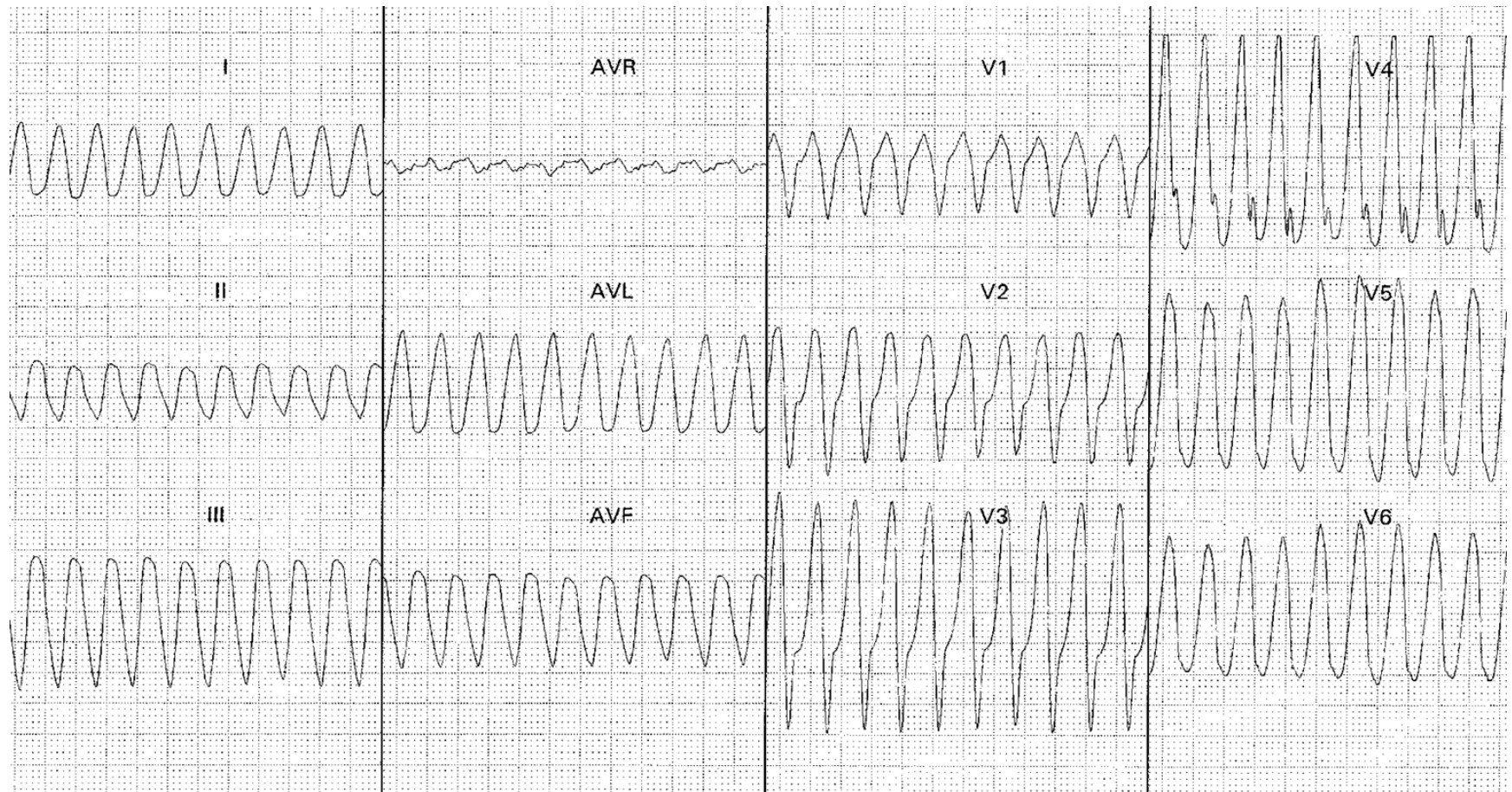
Taquicardia con QRS ancho.
Algoritmo diagnóstico




Taquiarritmias



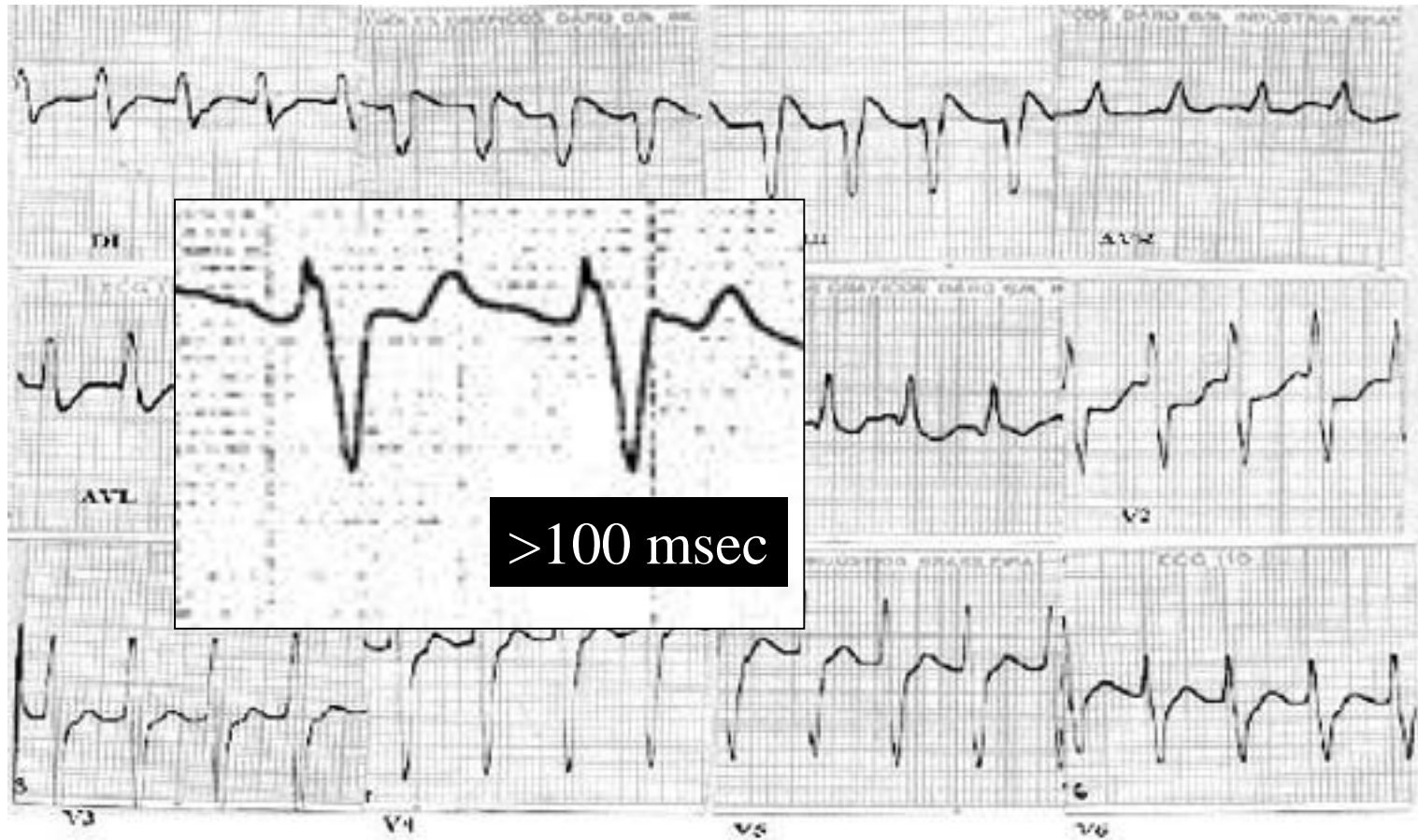
Ausencia R/S




Taquiarritmias



R nadir de S >100ms

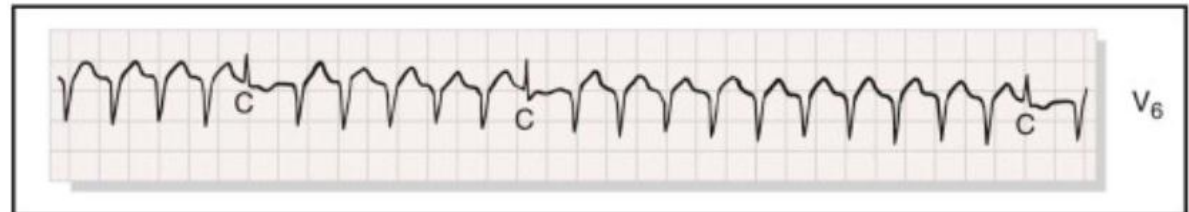
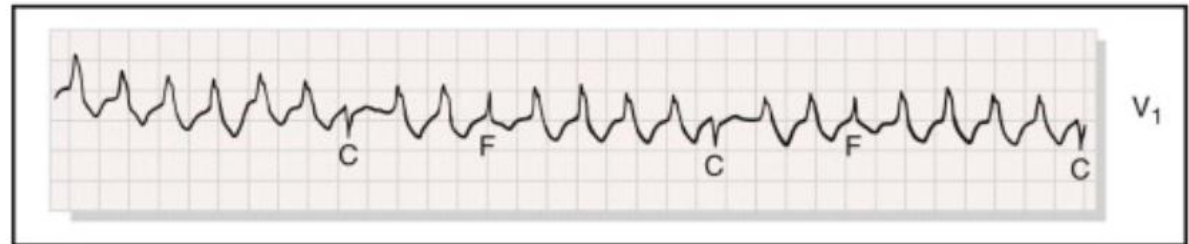
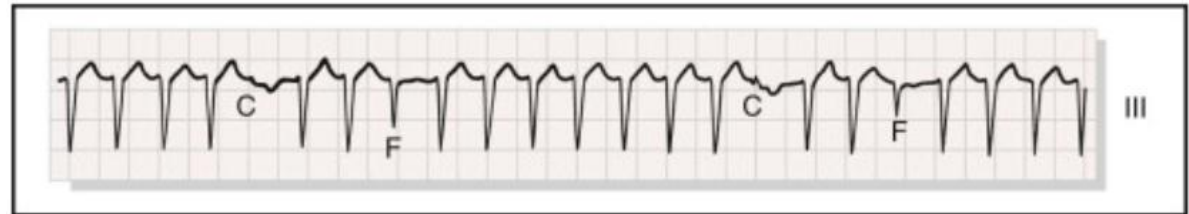
Taquiarritmias




Disociación AV

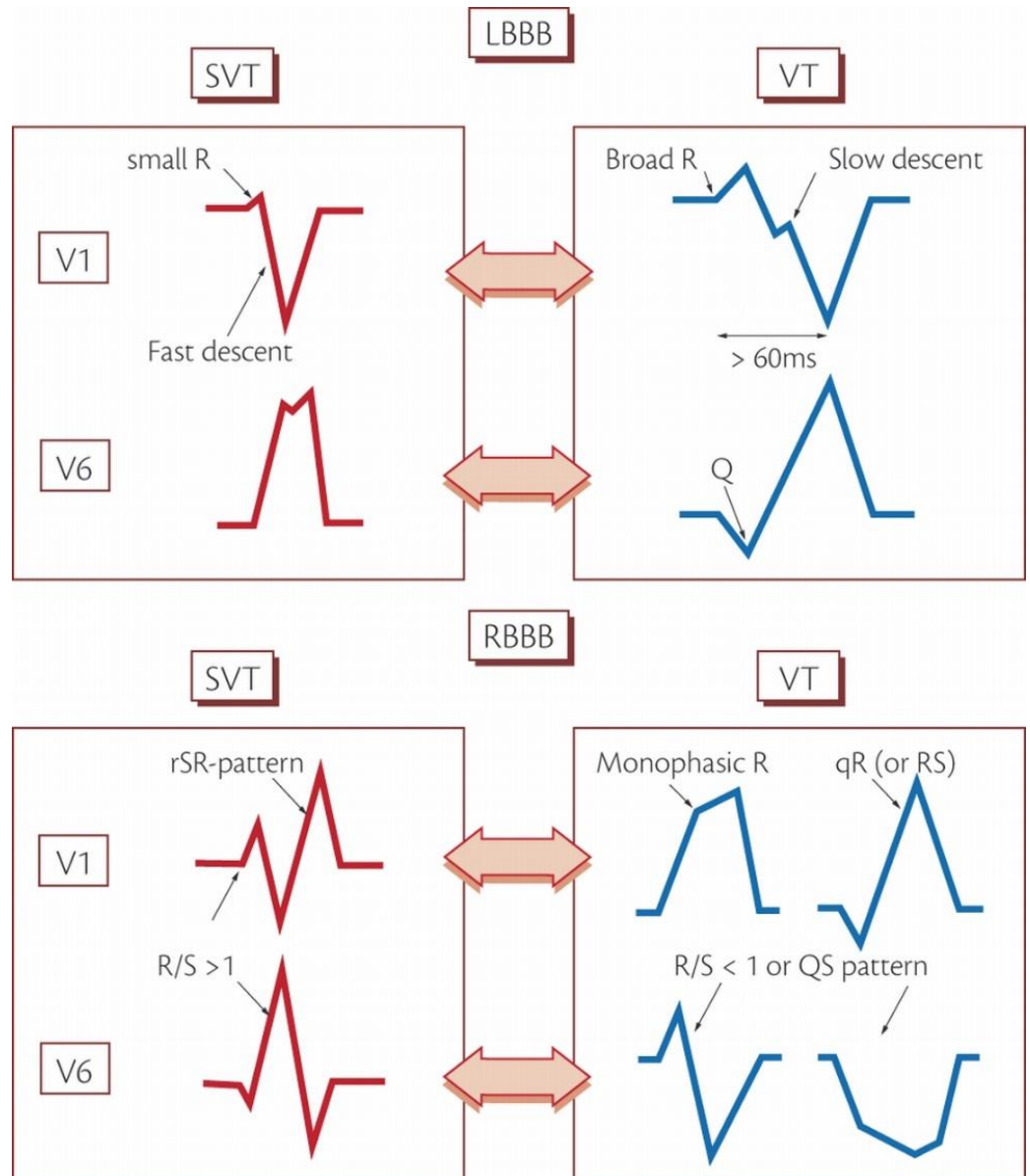
- Fusión
- Captura




Taquiarritmias



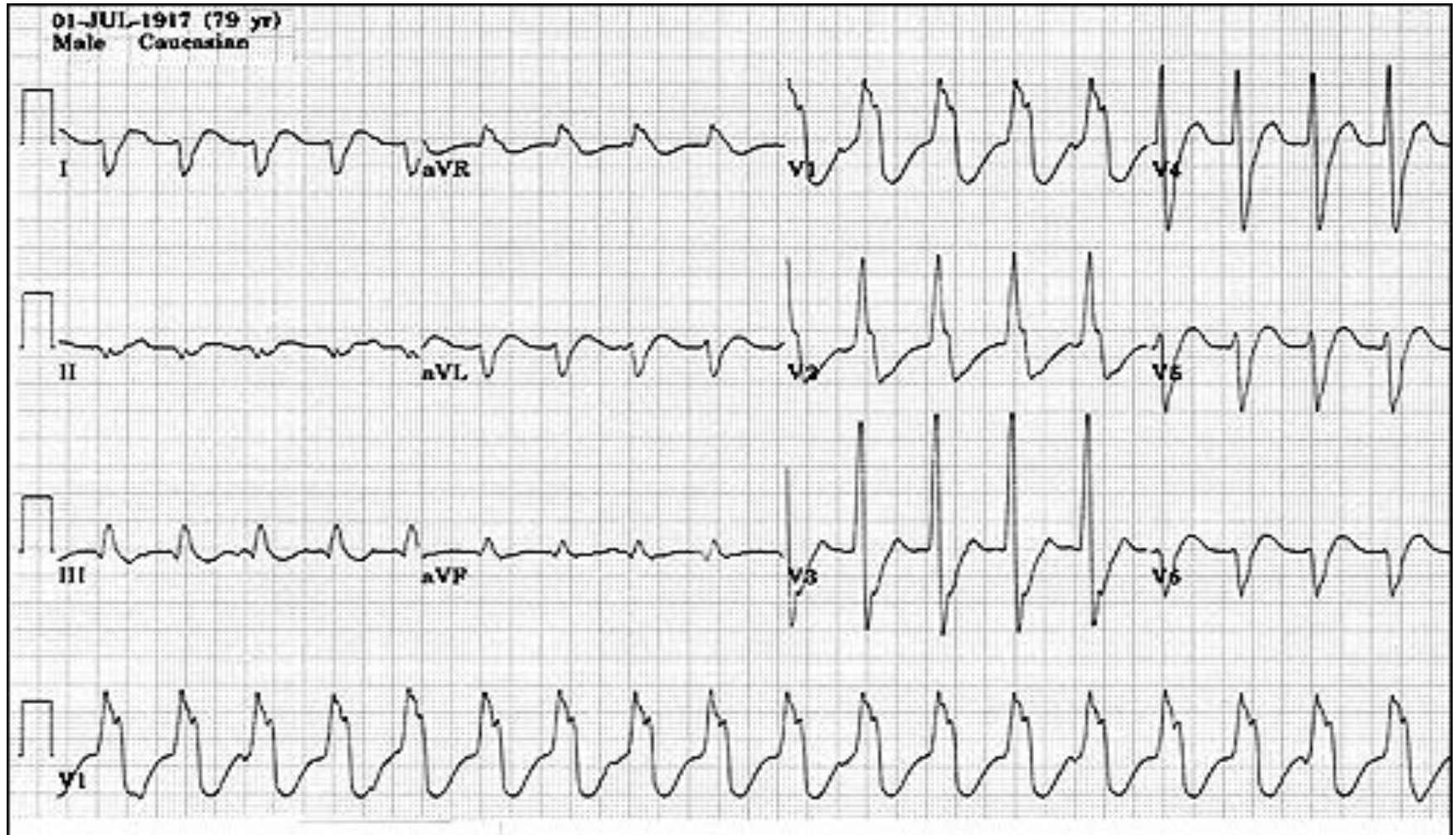
Criteria morfológicos



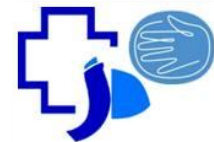Taquiarritmias



Criteria morfológicos



Taquiarritmias



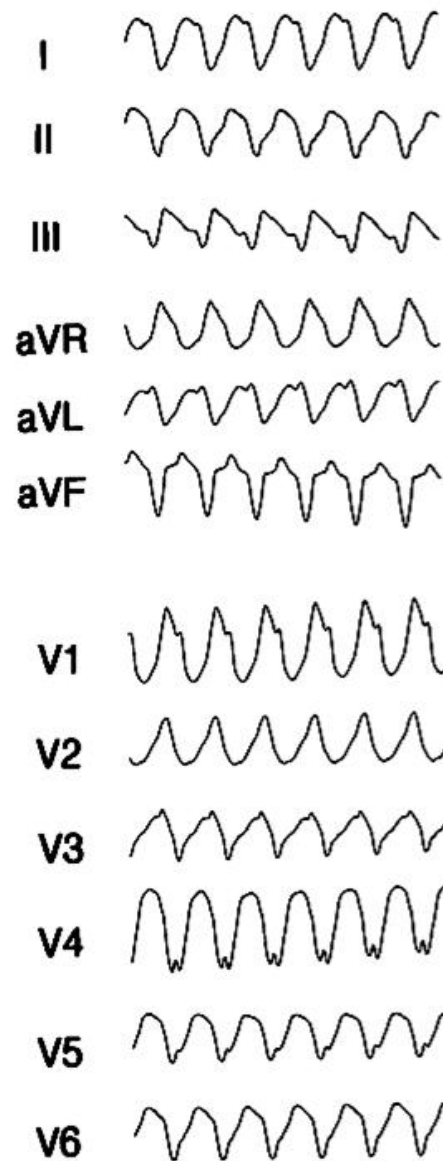
Taquicardia ventricular

Monomorfa

- Cardiopatía estructural (cardiopatía isquémica crónica, MCD)
- Sin cardiopatía estructural

Polimorfa

- QT normal (isquemia aguda, Sme. Brugada)
- QT largo (congenito, adquirido)



Taquiarritmias



Taquicardia ventricular

Monomorfa

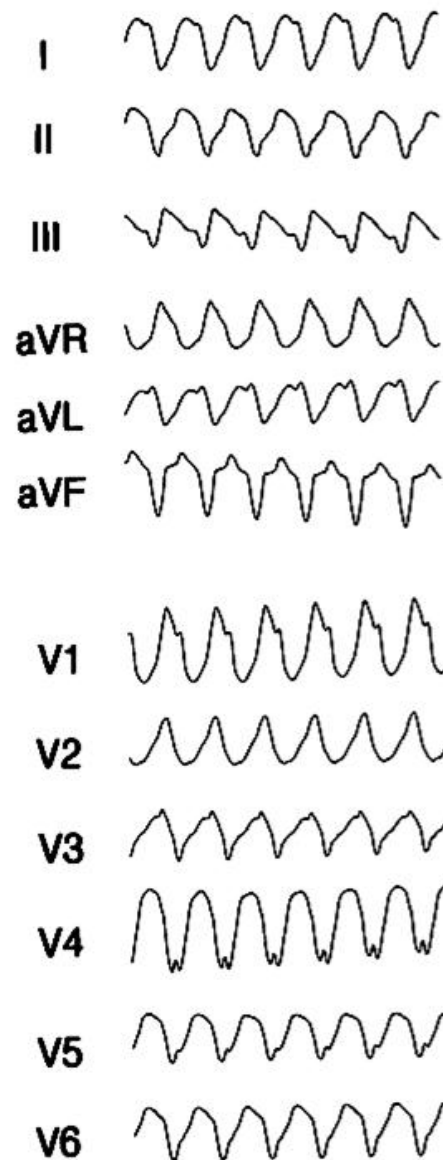
Con cardiopatía estructural

Tratamiento:


- CVE sincronizada
- Drogas:

Amiodarona (150mg ev en 10min)

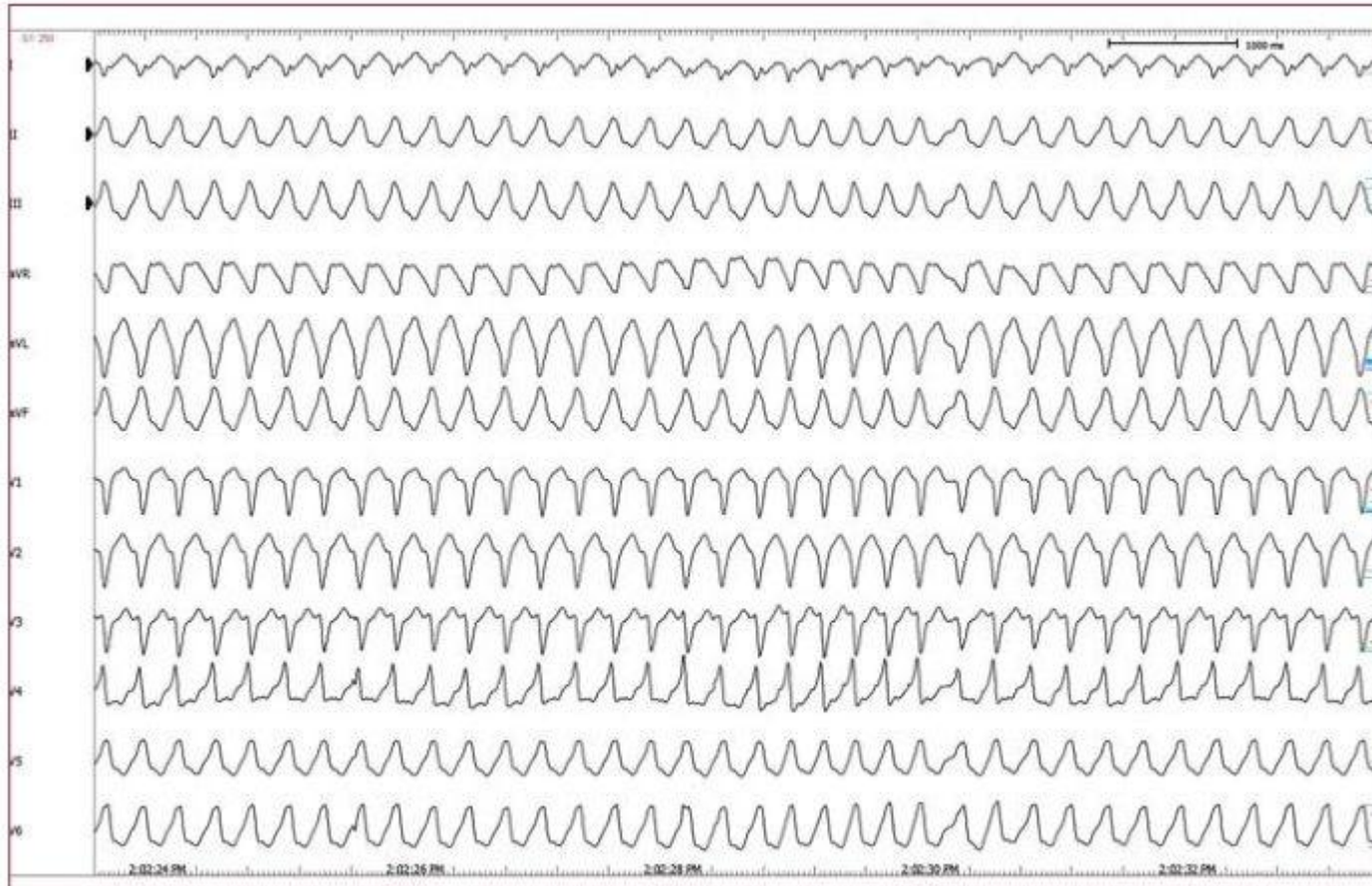
Lidocaína (0,5-0,75mg/kg ev en bolo)




Taquiarritmias



Taquicardia ventricular

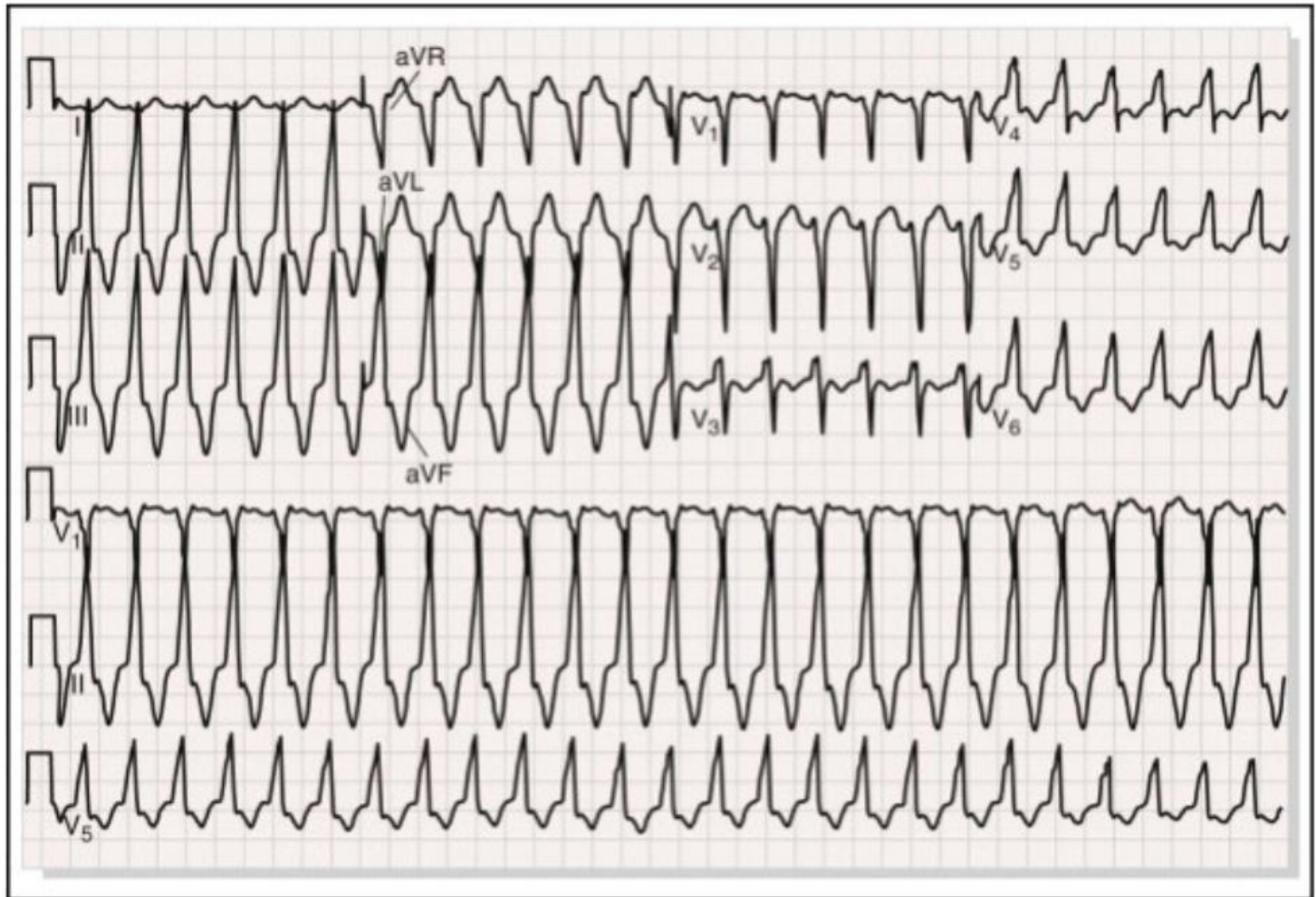


Taquiarritmias




Taquicardia ventricular

TSVD



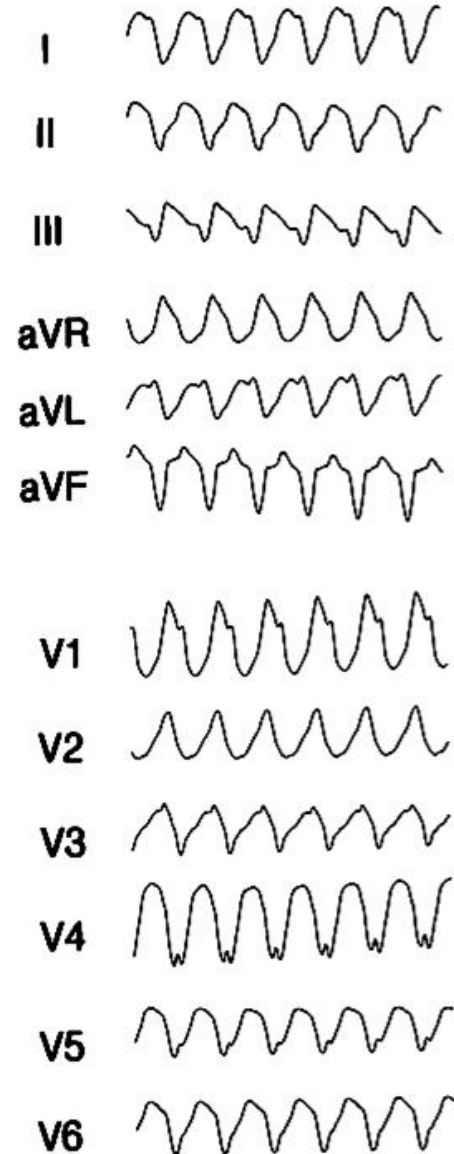
Taquiarritmias




Taquicardia ventricular

Polimorfa

- QT normal (isquemia aguda, disturbios electrolíticos)
- QT largo (congenito, adquirido)



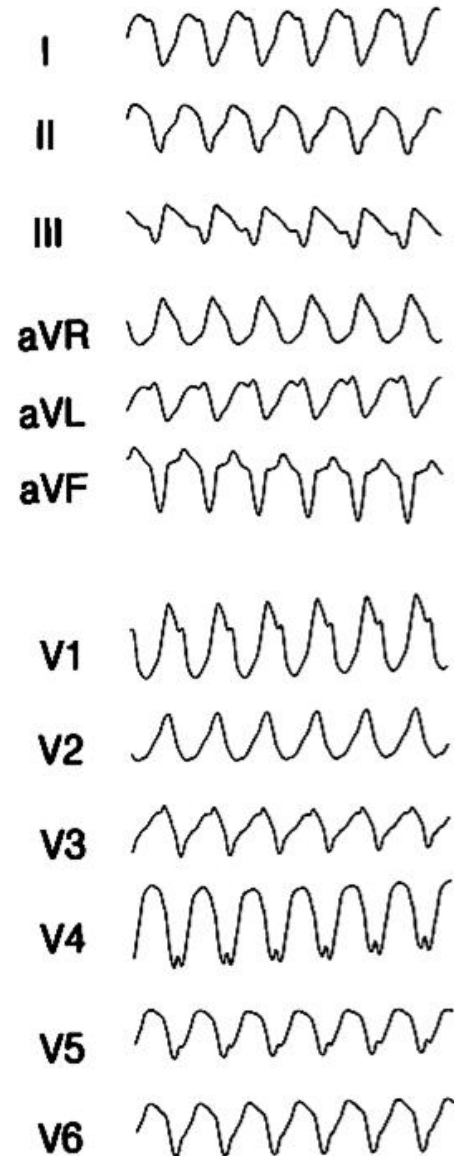
Taquiarritmias



Taquicardia ventricular

Polimorfa

- QT normal (isquemia aguda)
- Tratamiento:
CVE
Revascularización
Drogas: lidocaína. Amiodarona



Taquiarritmias



Taquicardia ventricular

Polimorfa

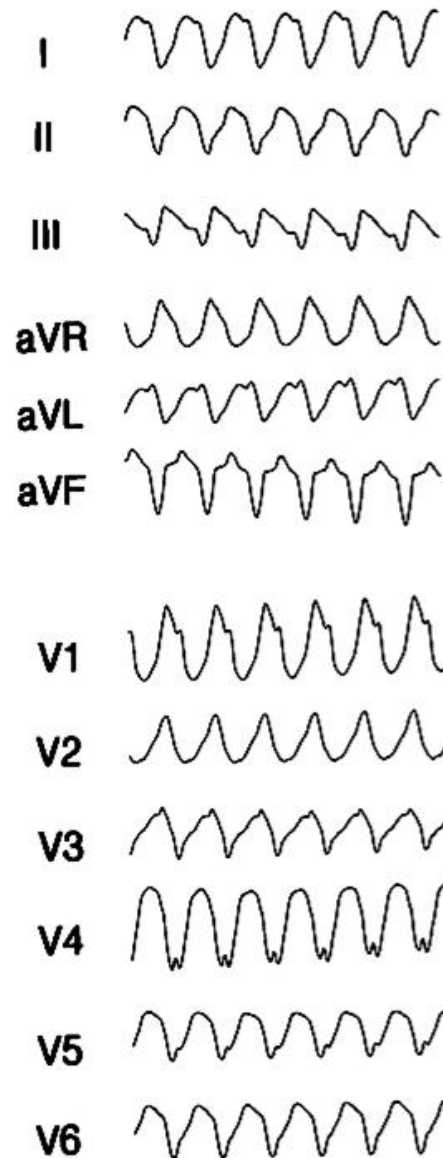
QT largo Adquirido:

Drogas


- Antiarrítmicos (IA-IC)
- Descongestivos nasales (terfenadina)
- Antibióticos (macrólidos)
- Cisapride

Bradicardia severa

Lesiones del SNC

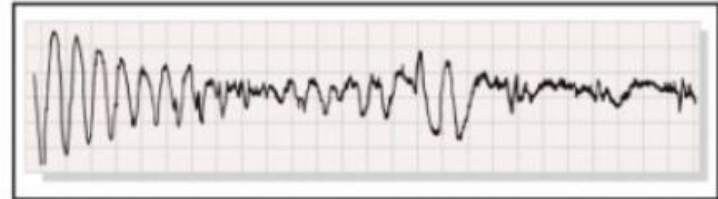
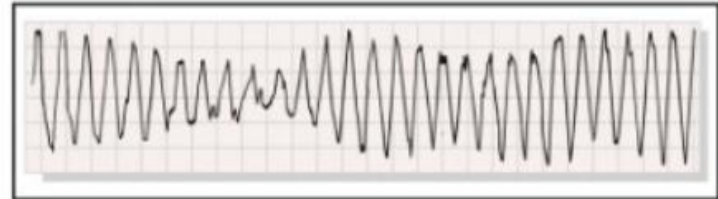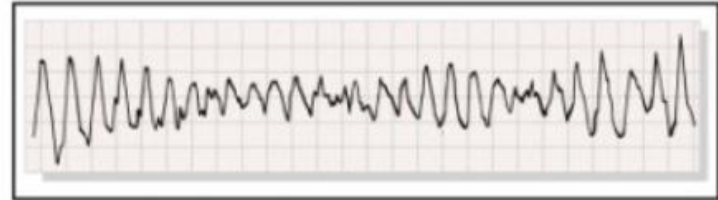
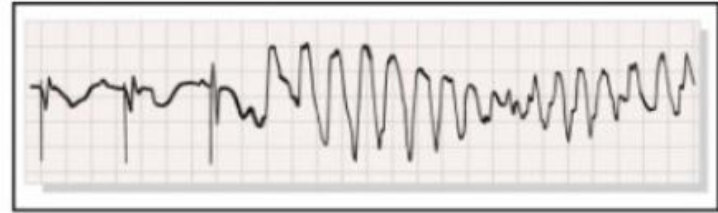


Taquiarritmias



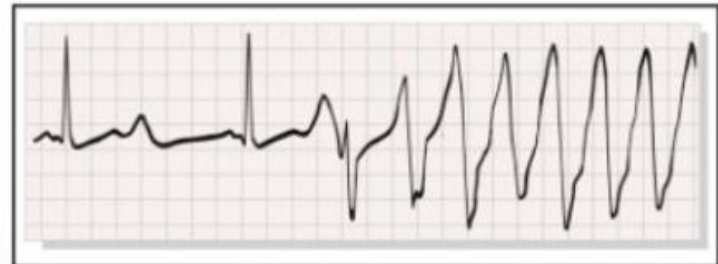Taquicardia ventricular

Pte con MCP VVI. QT largo




A

Pte en tto con terfenadina.



B

Taquiarritmias



Taquicardia ventricular

Polimorfa

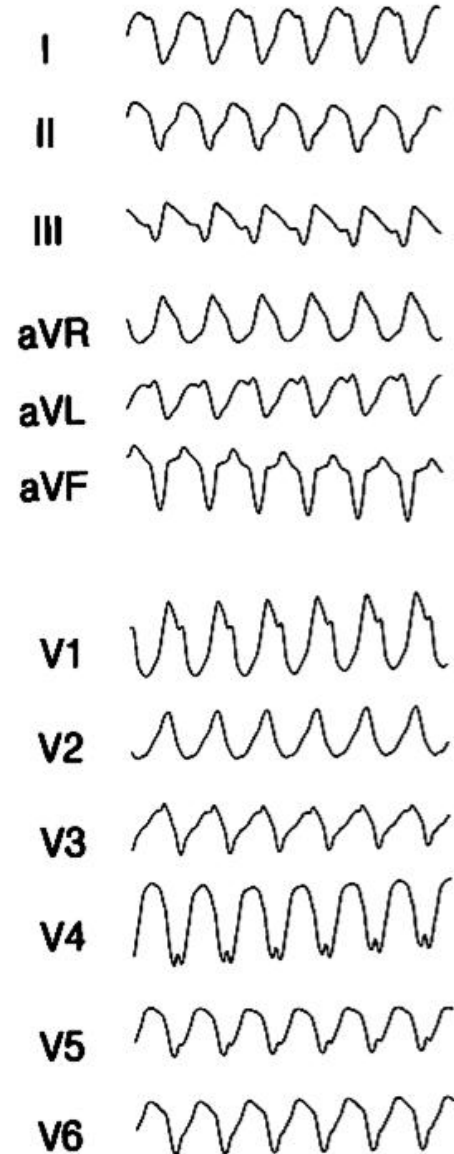
➤ QT largo

➤ Tratamiento:


CVE

Corregir trastorno electrolítico

Drogas: magnesio. Sobreestimulación con mcp transitorio. Isoproterenol. lidocaína.

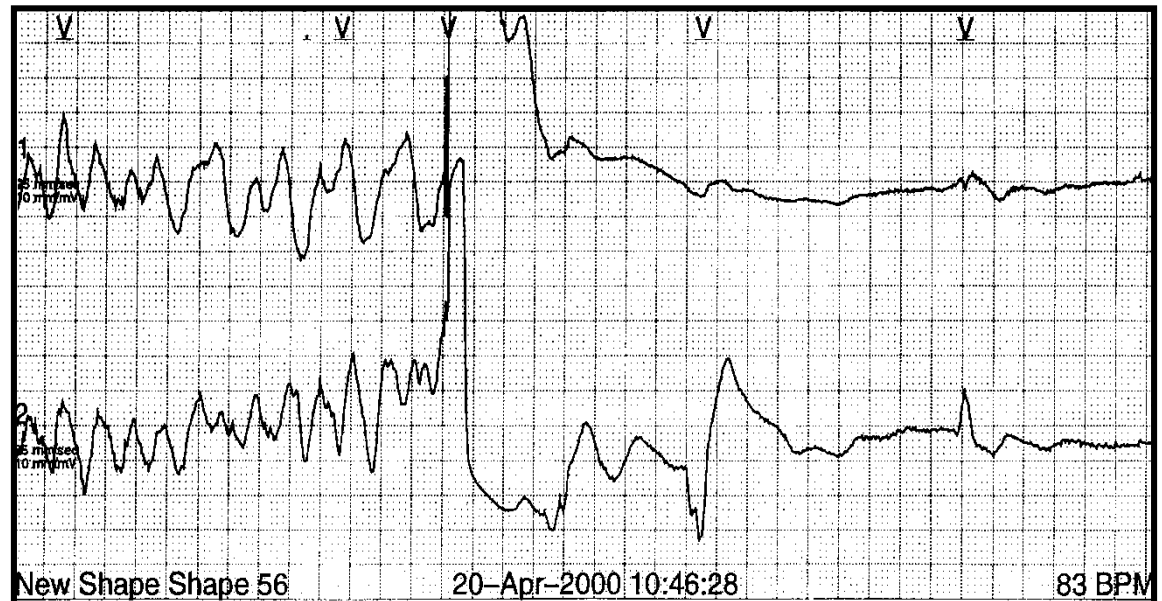
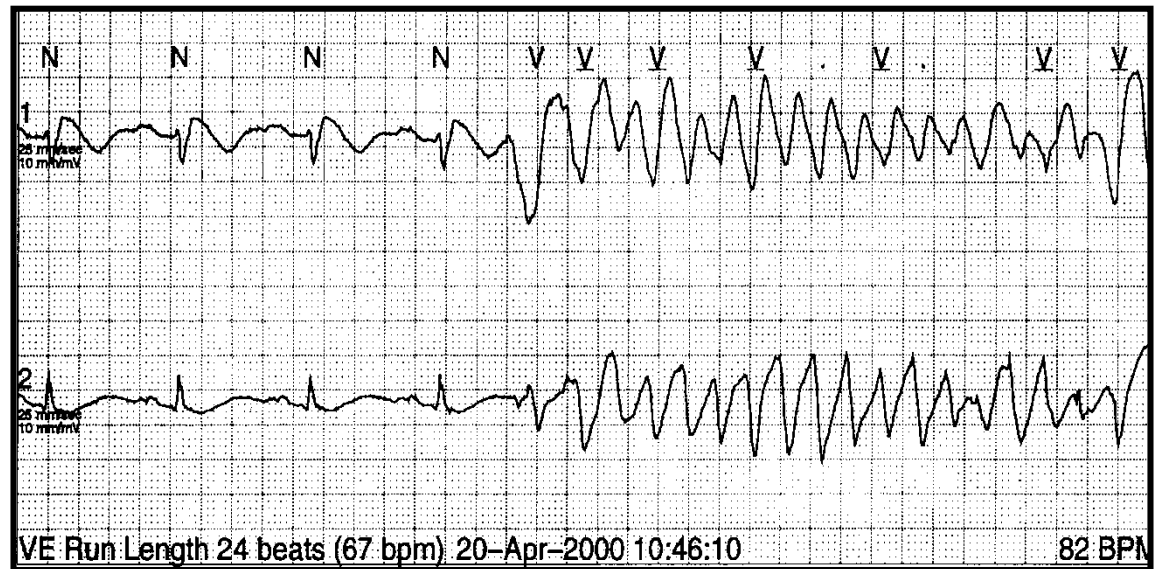


Taquiarritmias




Taquicardia ventricular


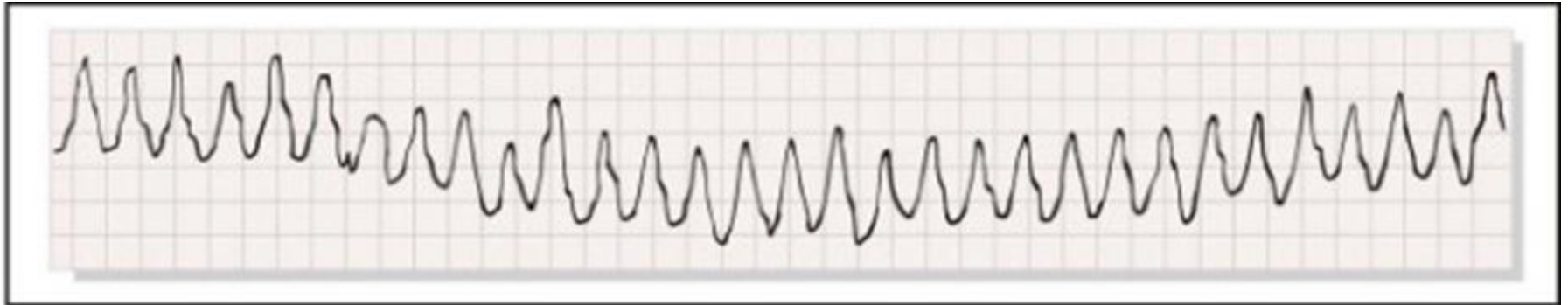
CVE
Sulfato Mg⁺⁺
Isoproterenol
MCP transitorio



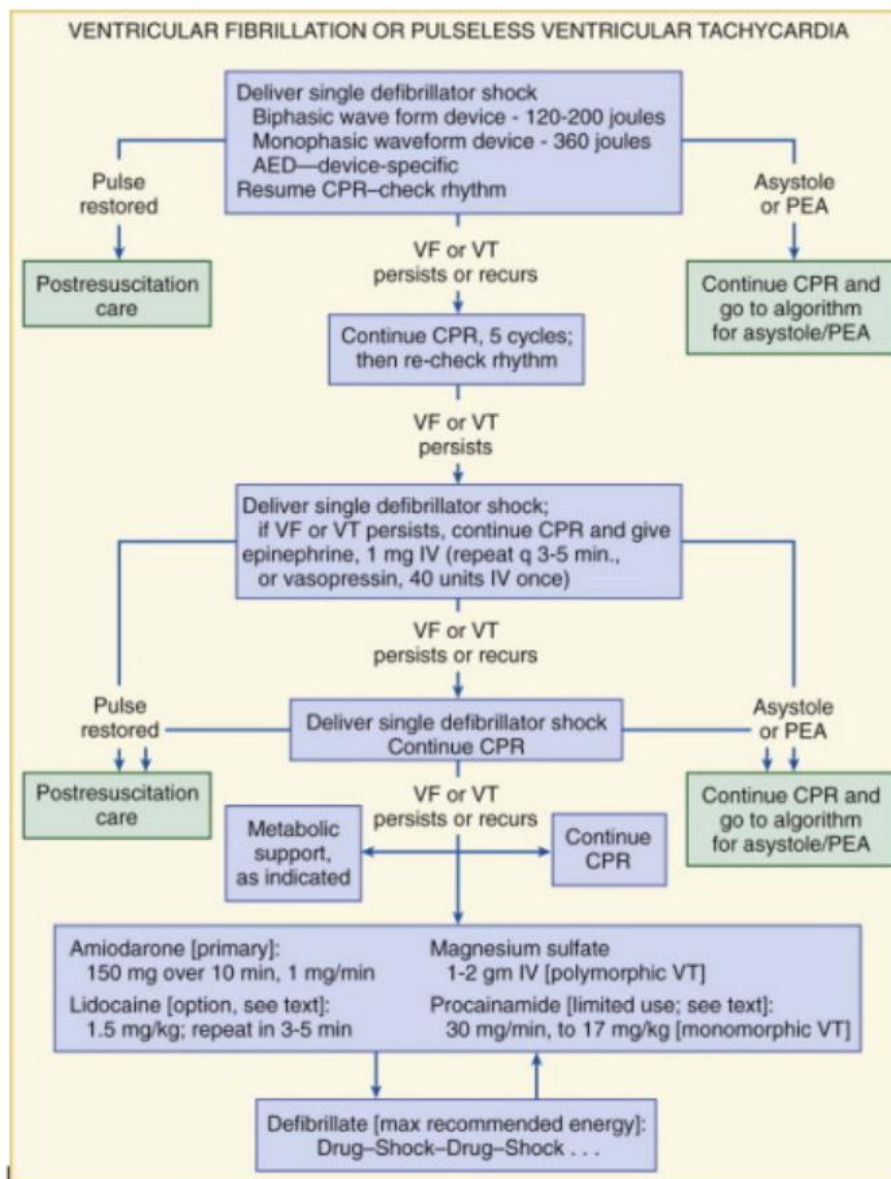
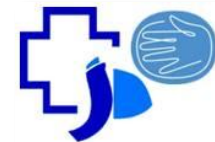
Taquiarritmias



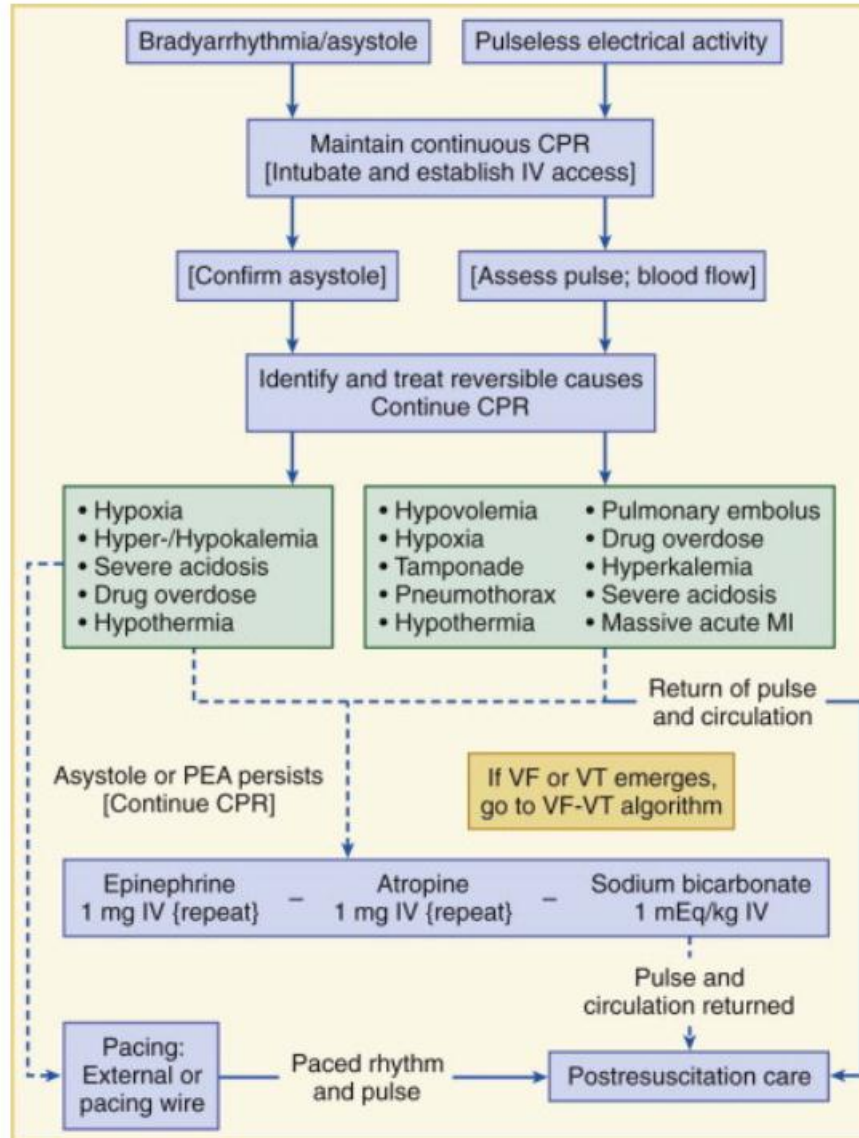

Fibrilación ventricular




Taquiarritmias



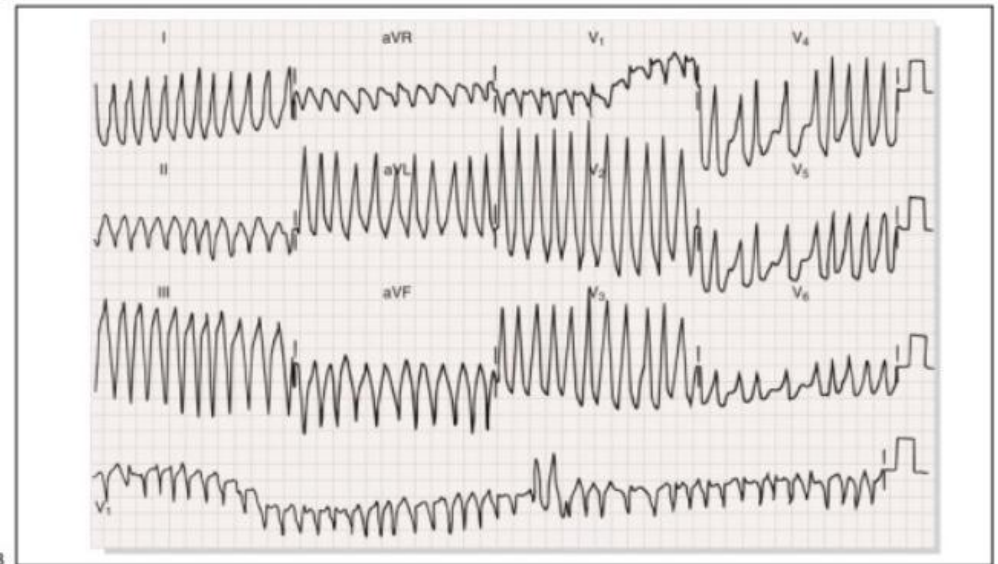
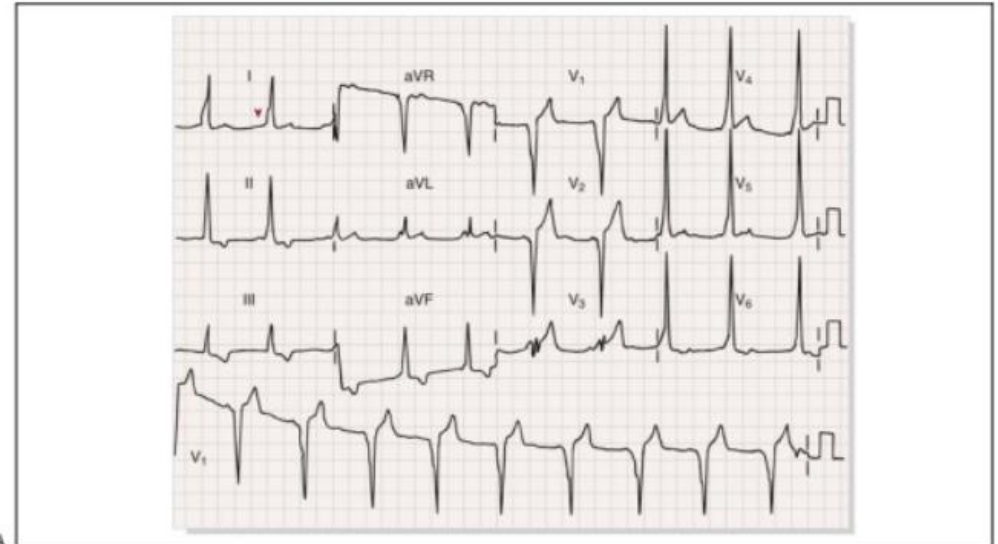
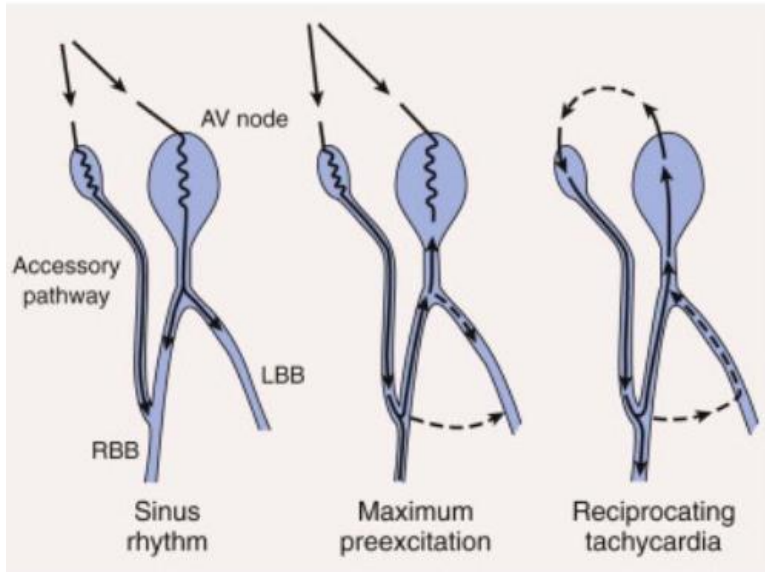
Taquiarritmias




Taquiarritmias



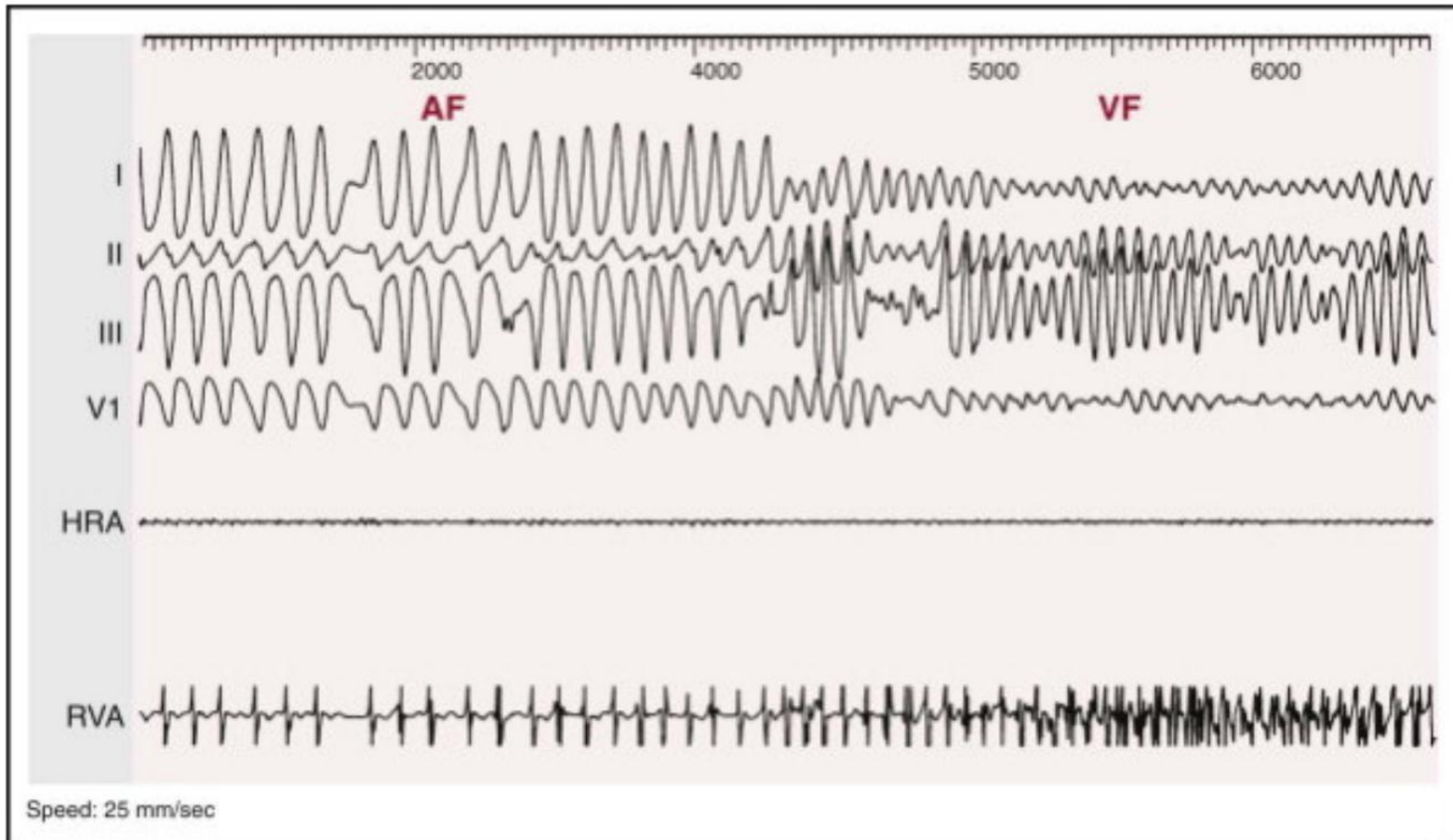
Fibrilación auricular pre-excitada



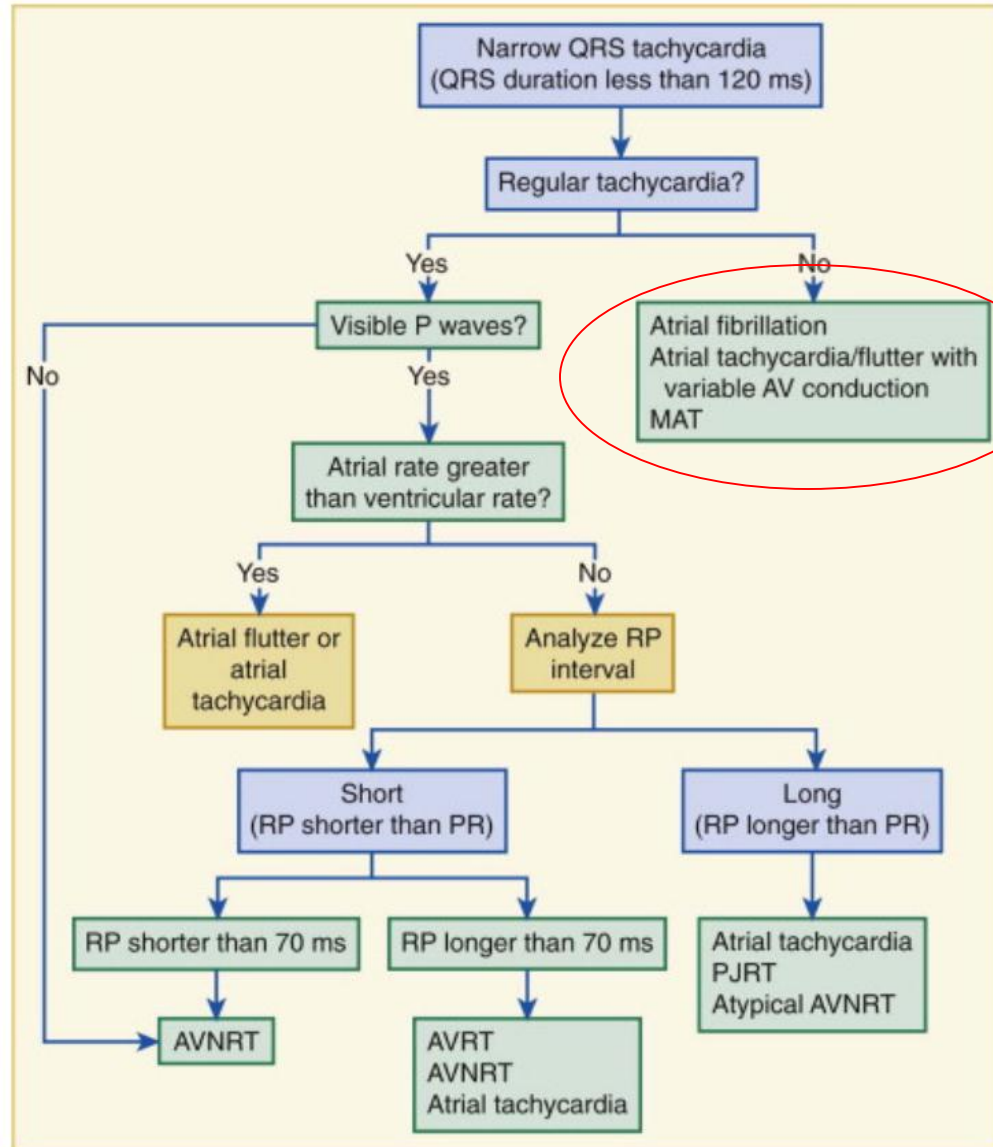

Taquiarritmias




Fibrilación auricular pre-excitada



Taquiarritmias



Taquiarritmias




Taquicardia supraventricular

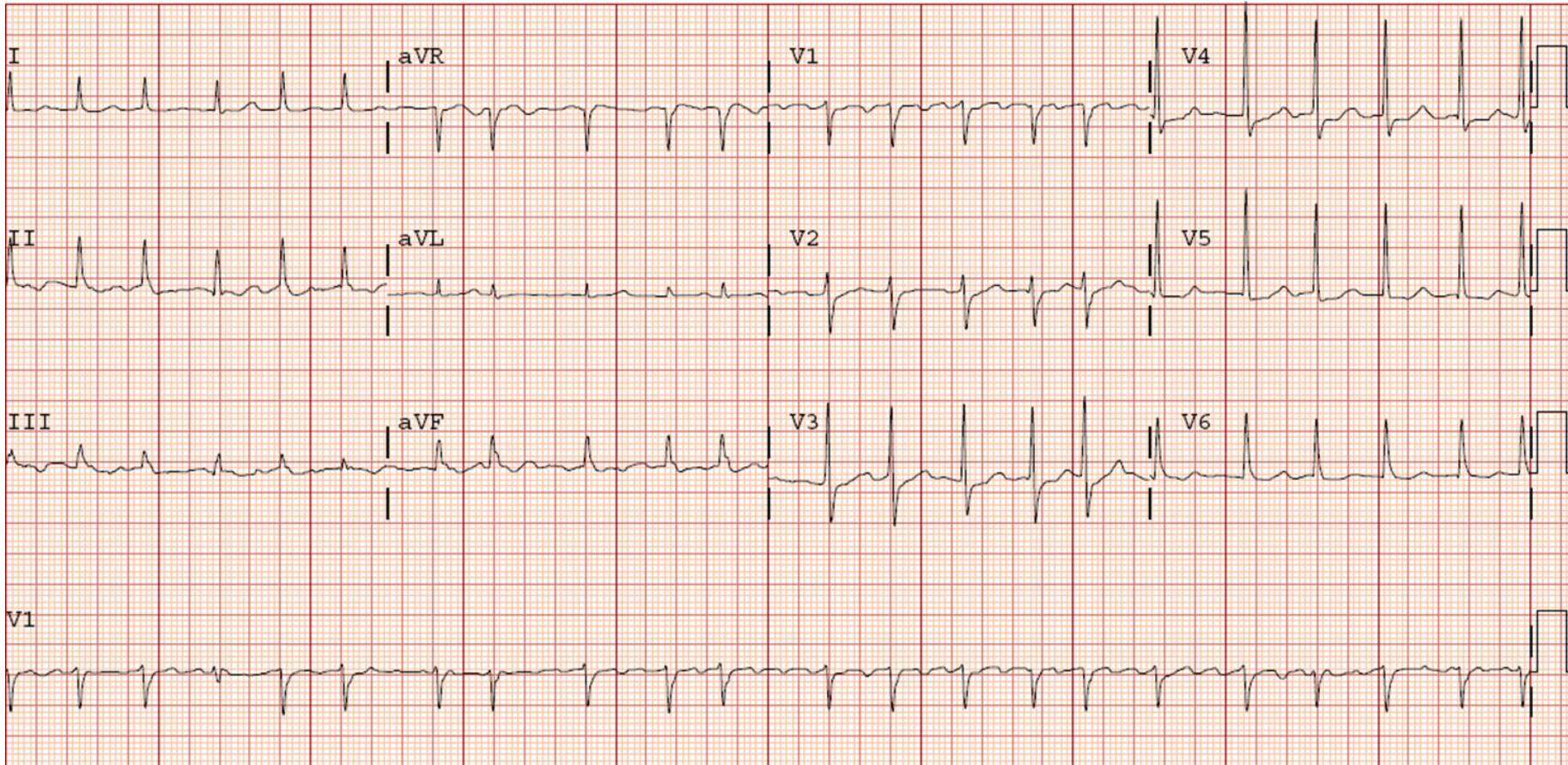
Evaluar estado hemodinámico

- Inestable: CVE
- Estable: maniobras diagnósticas (MSC-adenosina)

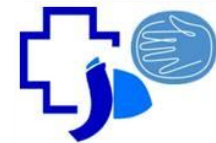
Taquiarritmias



Fibrilación auricular

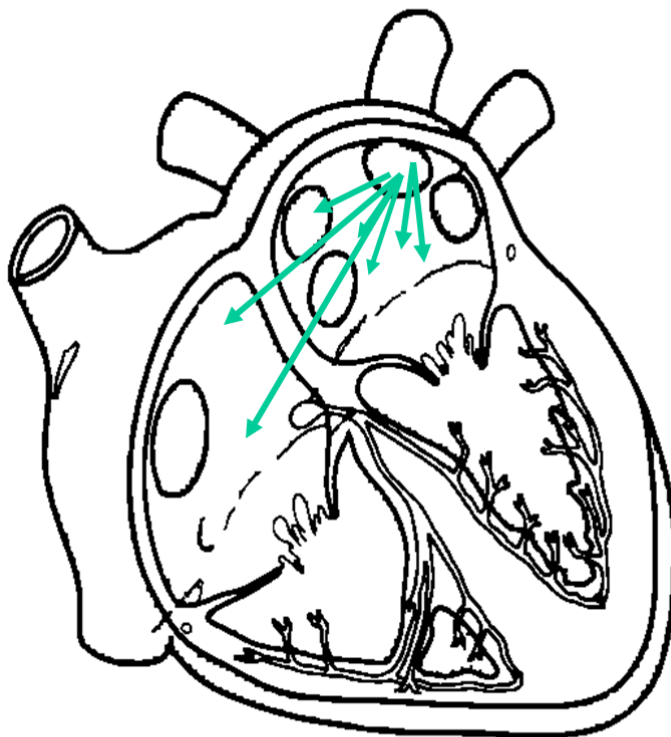

Taquiarritmias




Fibrilación auricular

Fibrilação Atrial Paroxística - Mecanismos -




Atividade Focal Rápida



Múltiplos Circuitos Reentrantes

Taquiarritmias



Fibrilación auricular

PAROXÍSTICA

Terminación espontánea o con intervención dentro de 7 días de su inicio.

PERSISTENTE

> a 7 días

PERSISTENTE DE LARGA DURACIÓN

> 1 año


PERMANENTE

Decisión de dejar de intentar restaurar y / o mantener el RS

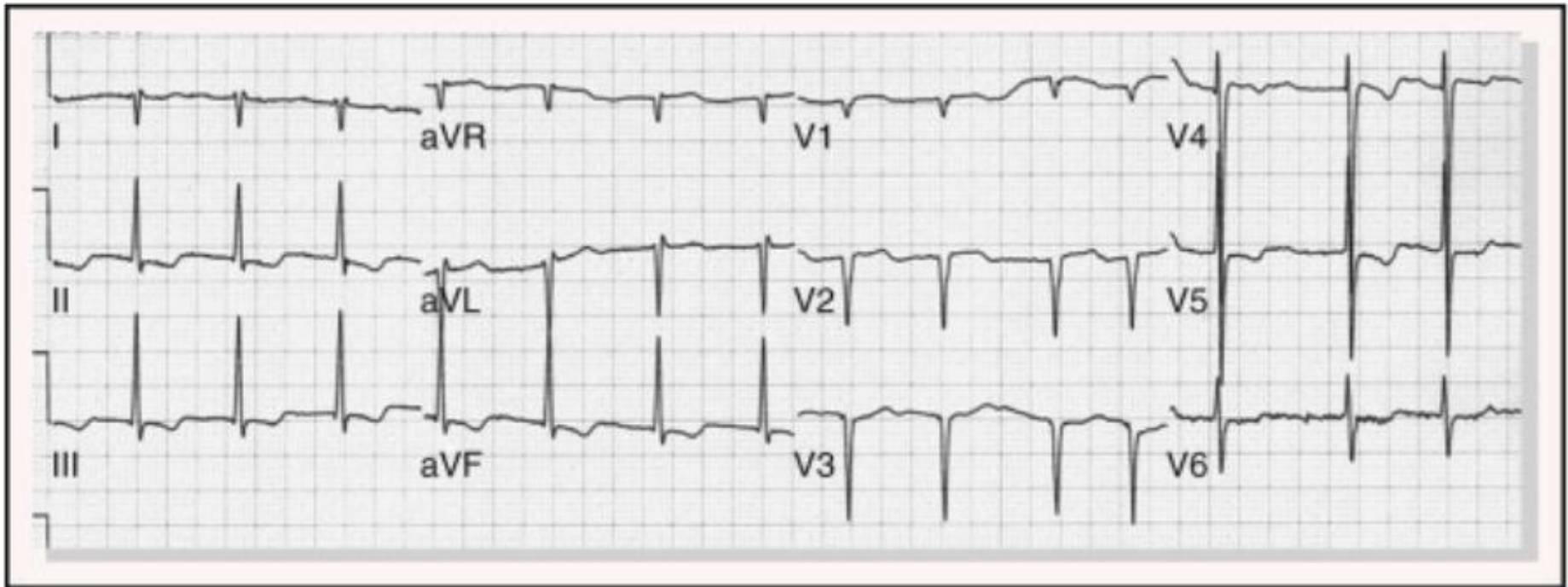
NO VALVULAR

Ausencia de Est. mitral reumática, Válv. protésica o mecánica o Válv mitral reparada


Taquiarritmias



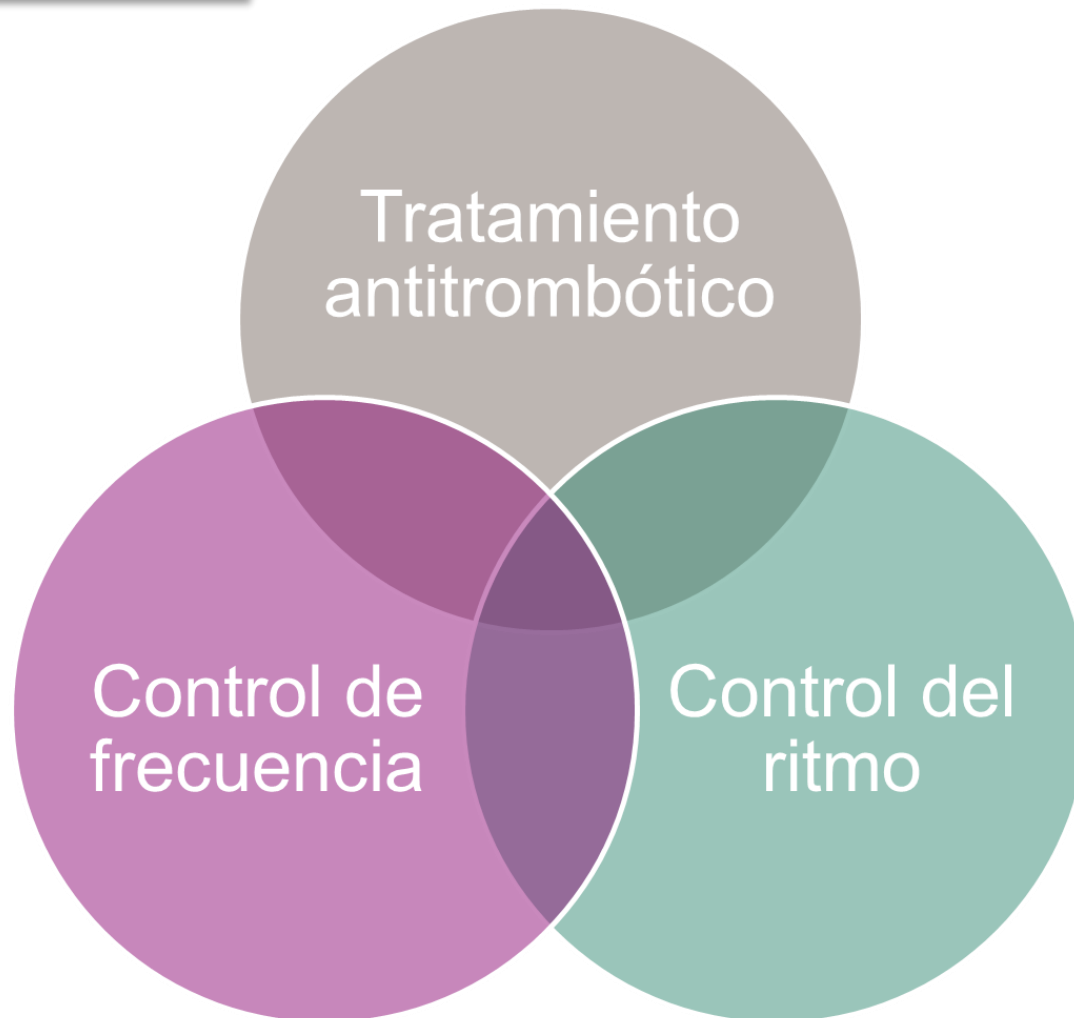
Fibrilación auricular




Taquiarritmias



Fibrilación auricular




Taquiarritmias



Fibrilación auricular

	CHA ₂ DS ₂ -VASc		CHA ₂ DS ₂ -VASc†	
Congestive HF	1		0	0
Hypertension	1		1	1.3
Age ≥75 y	2		2	2.2
Diabetes mellitus	1		3	3.2
Stroke/TIA/TE	2		4	4.0
Vascular disease (prior MI, PAD, or aortic plaque)	1		5	6.7
Age 65–74 y	1		6	9.8
Sex category (ie, female sex)	1		7	9.6
Maximum score	9		8	6.7
			9	15.20

Taquiarritmias



Fibrilación auricular. Control de FC

BB

- Los + efectivos
- FA aguda: Esmolol, propranolol y metoprolol EV
- FA crónica: Atenolol, metoprolol, nadolol, propranolol y sotalol VO

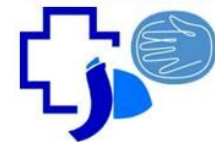
CALCIO ANTAGONISTA S

- FA aguda y crónica
- NO utilizar en:
 - Disfunción sistólica del VI e IC descompensada
 - Pre - excitación + FA

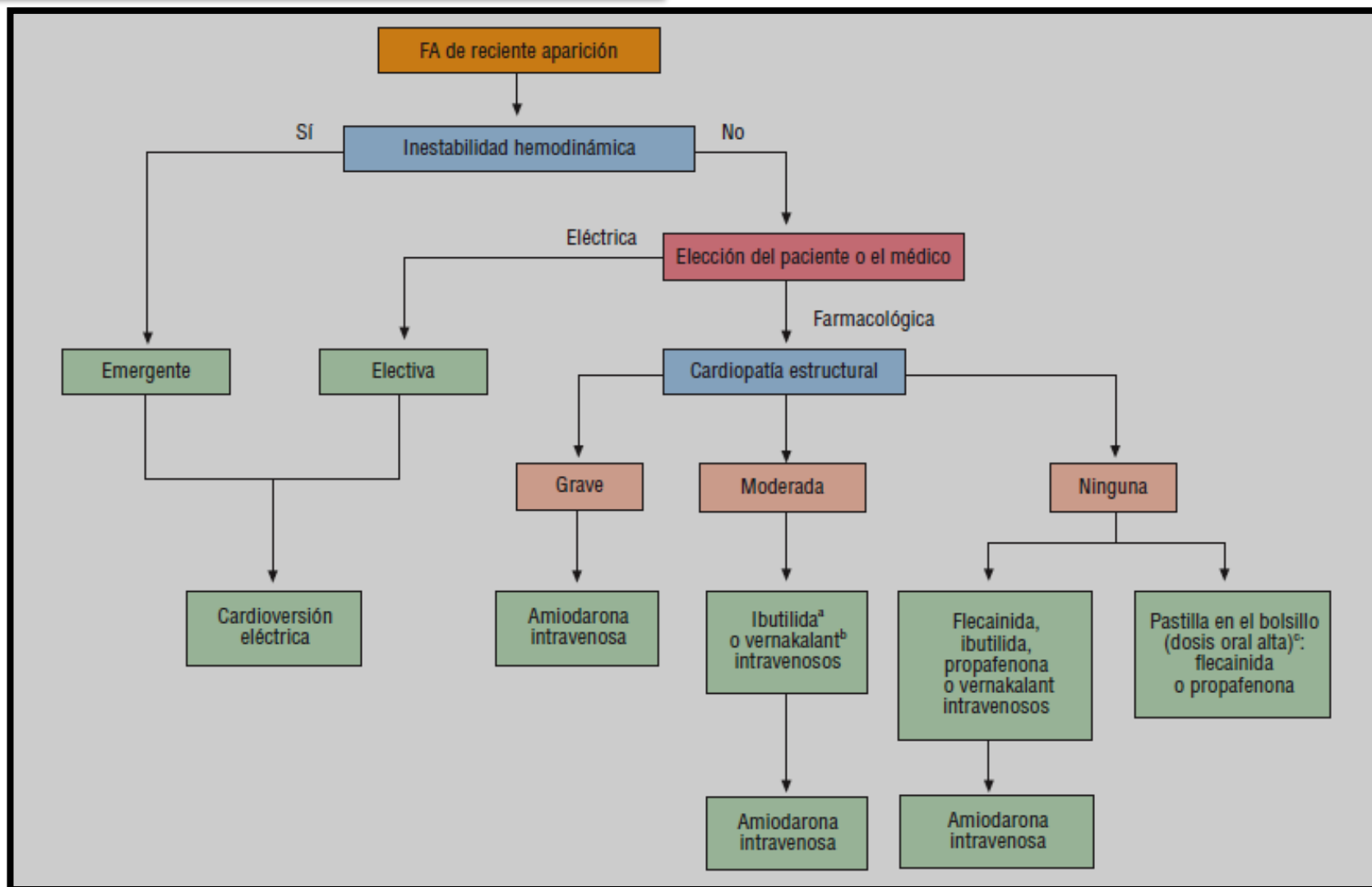
DIGOXINA

- **NO es de 1º elección.**
- Ineficaz en el control de la respuesta ventricular durante el ejercicio (combinar con BB o CA antagonistas)


Taquiarritmias



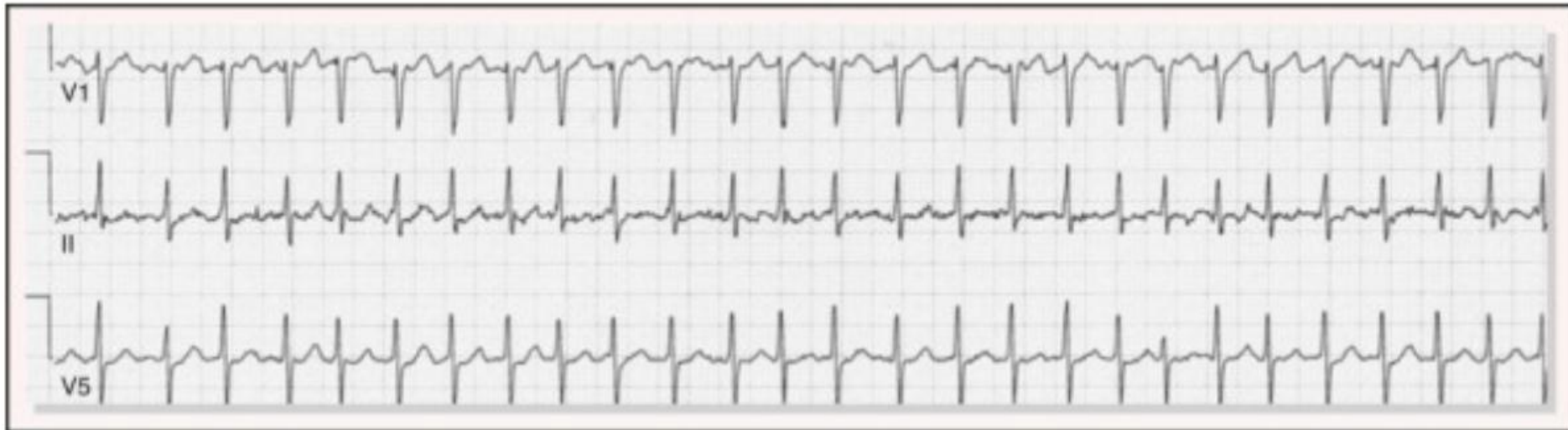Fibrilación auricular. Control de ritmo




Taquiarritmias



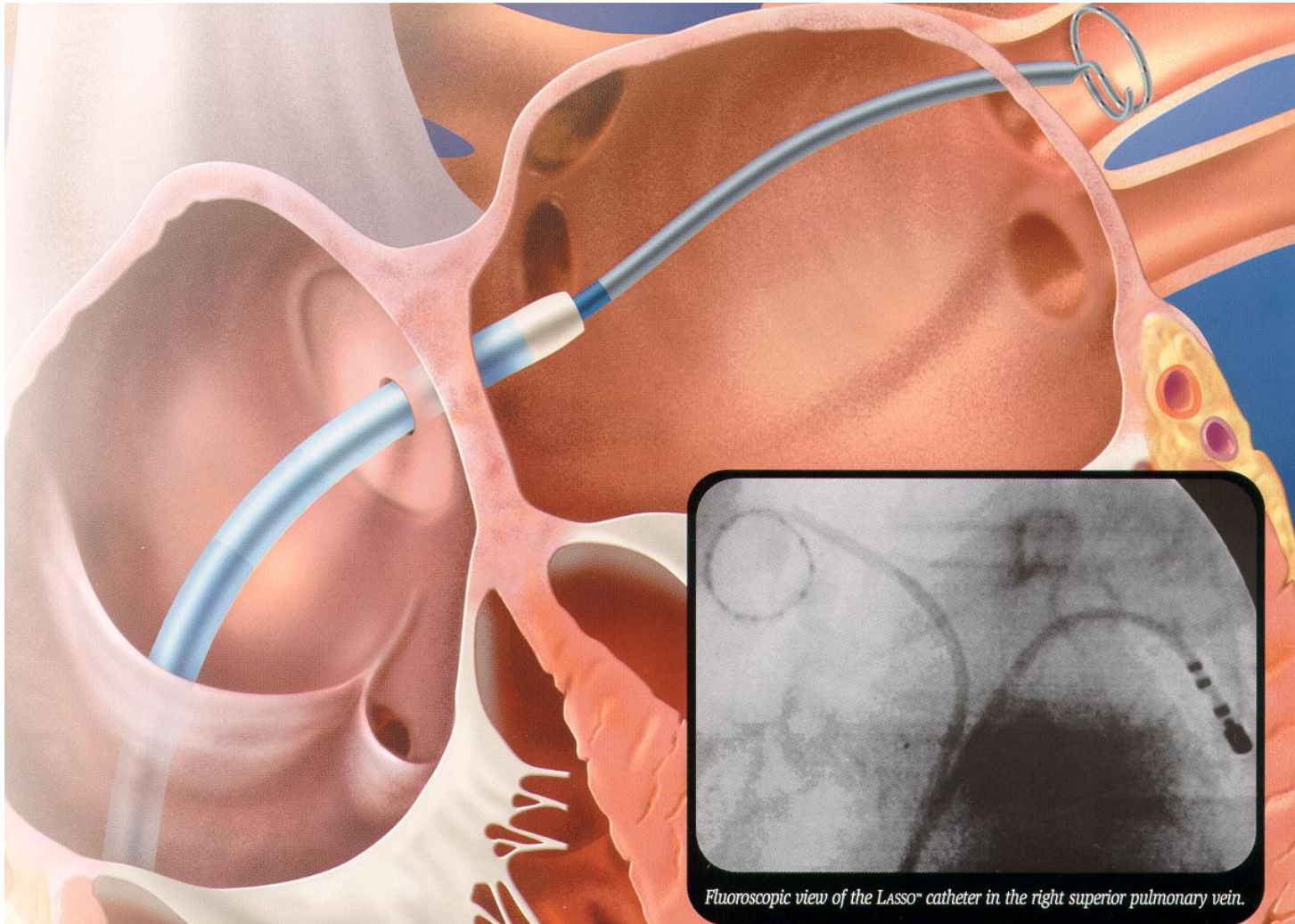
Fibrilación auricular



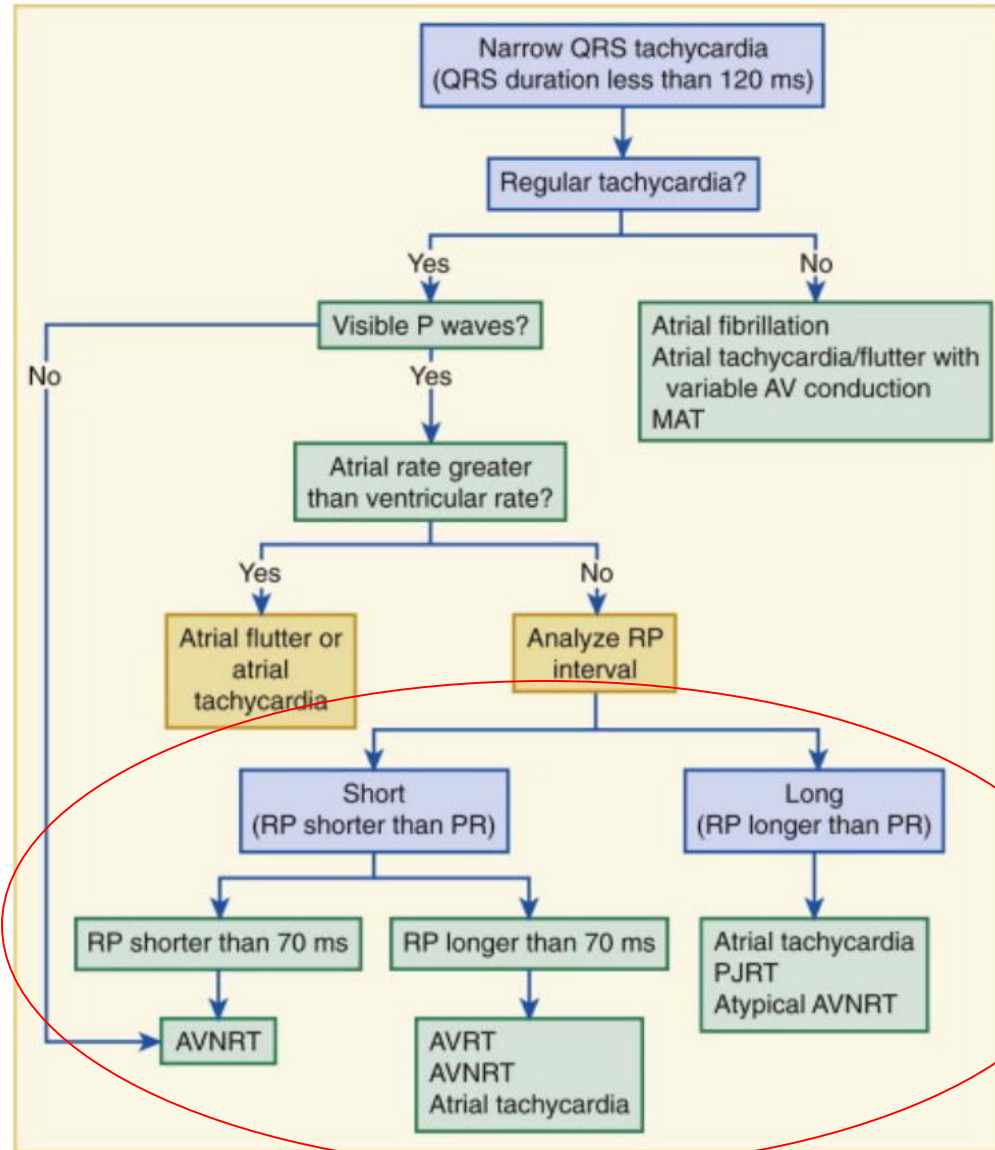

Taquiarritmias



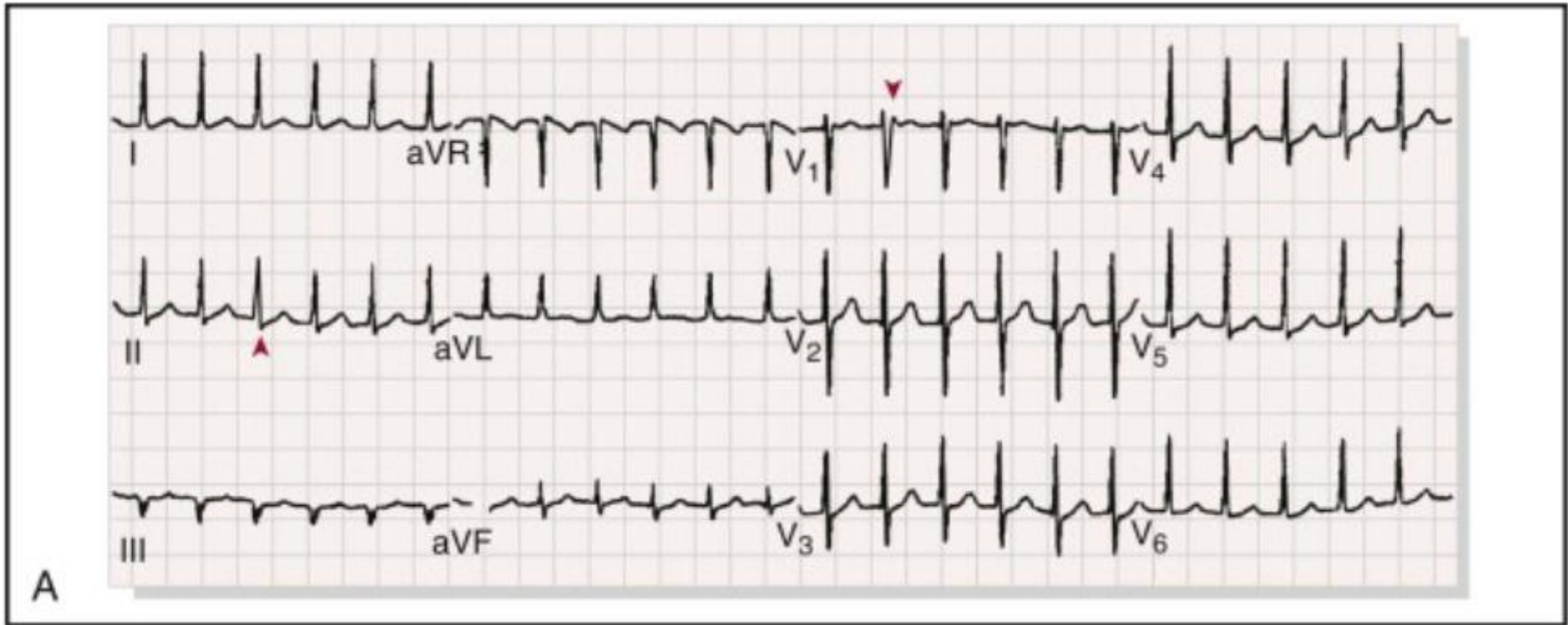

Fibrilación auricular




Taquiarritmias



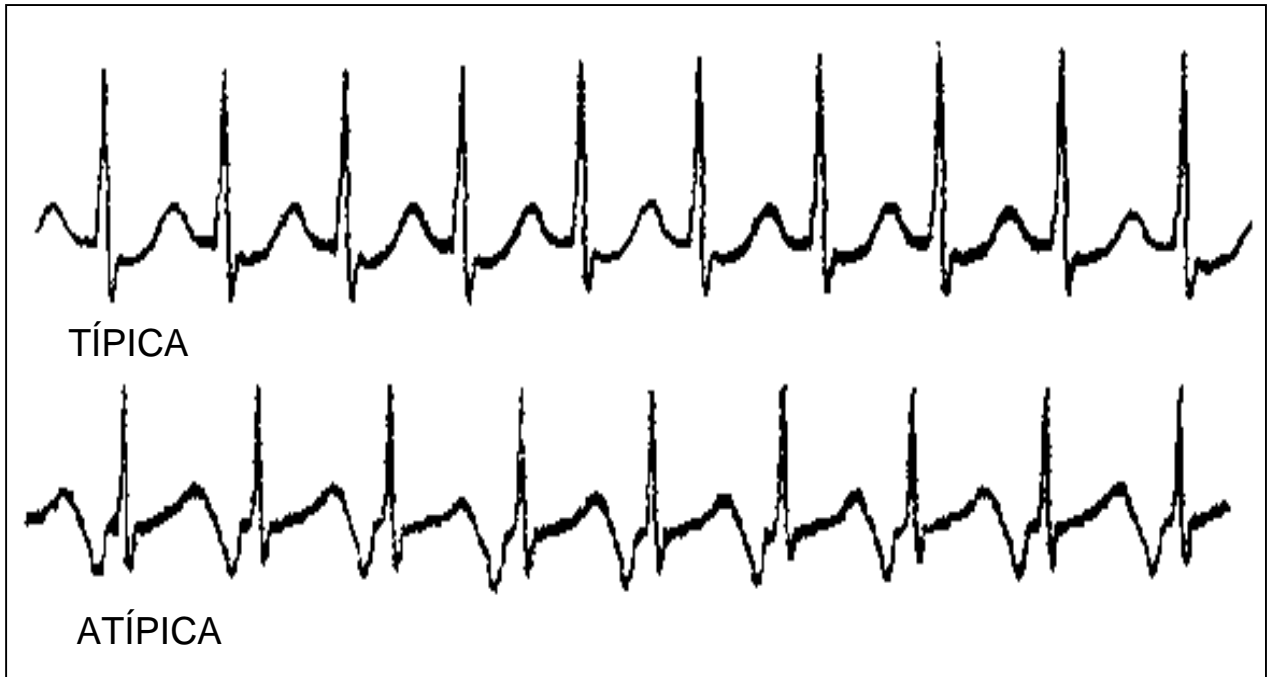
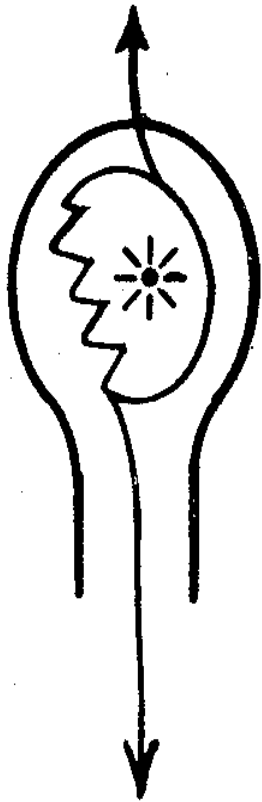
Taquiarritmias




Taquiarritmias



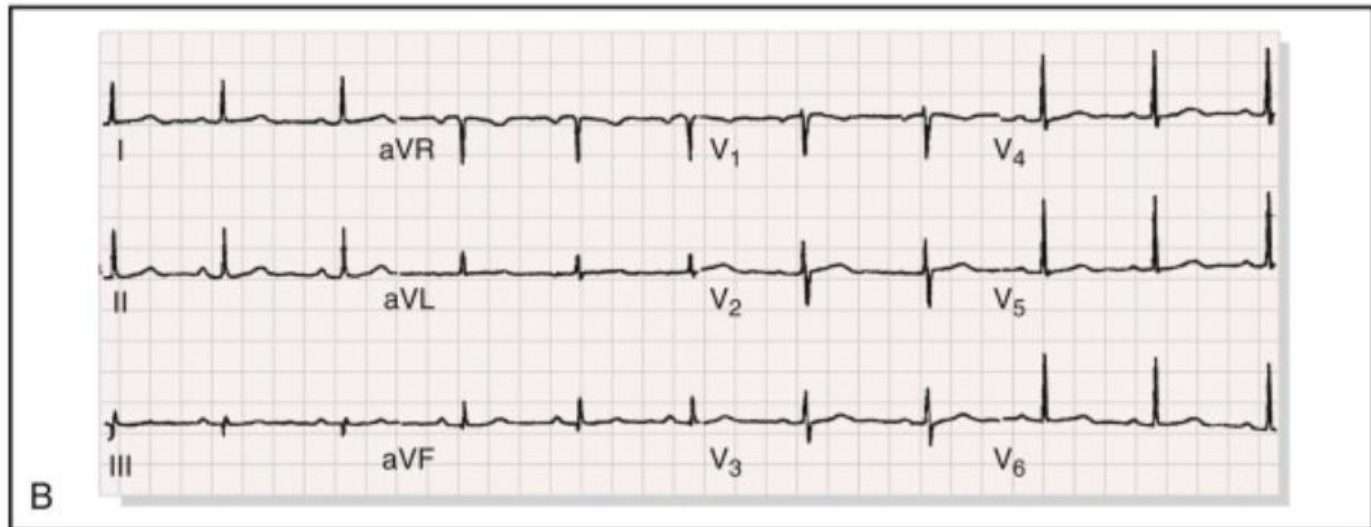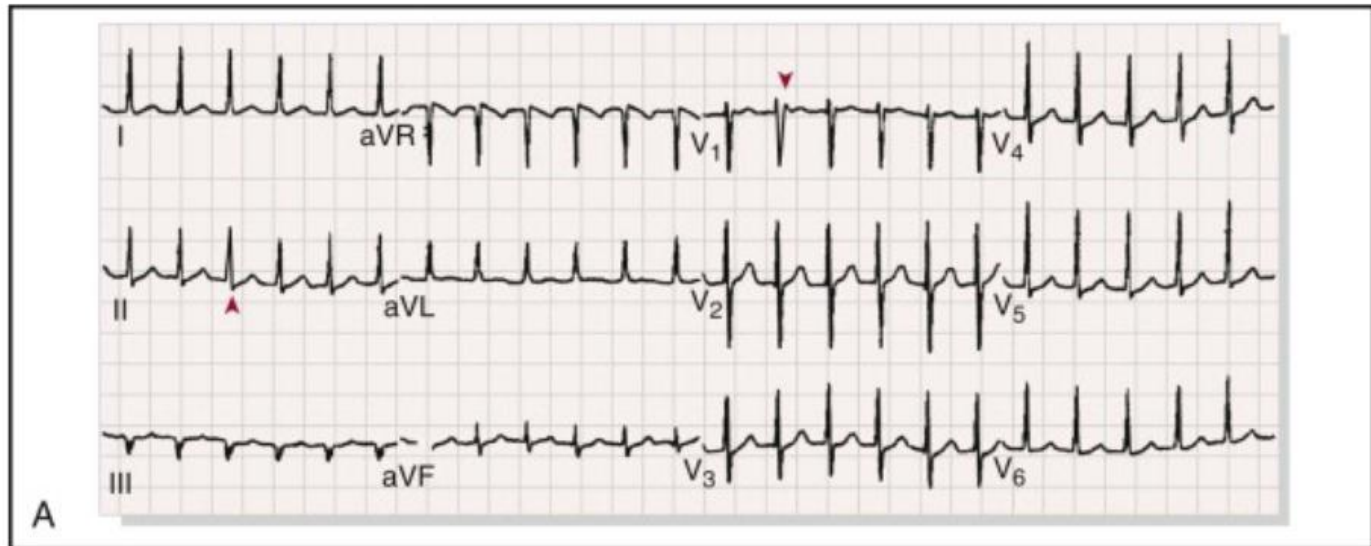
Taquicardia por reentrada intranodal



Taquiarritmias



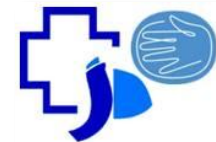
Taquicardia por reentrada intranodal





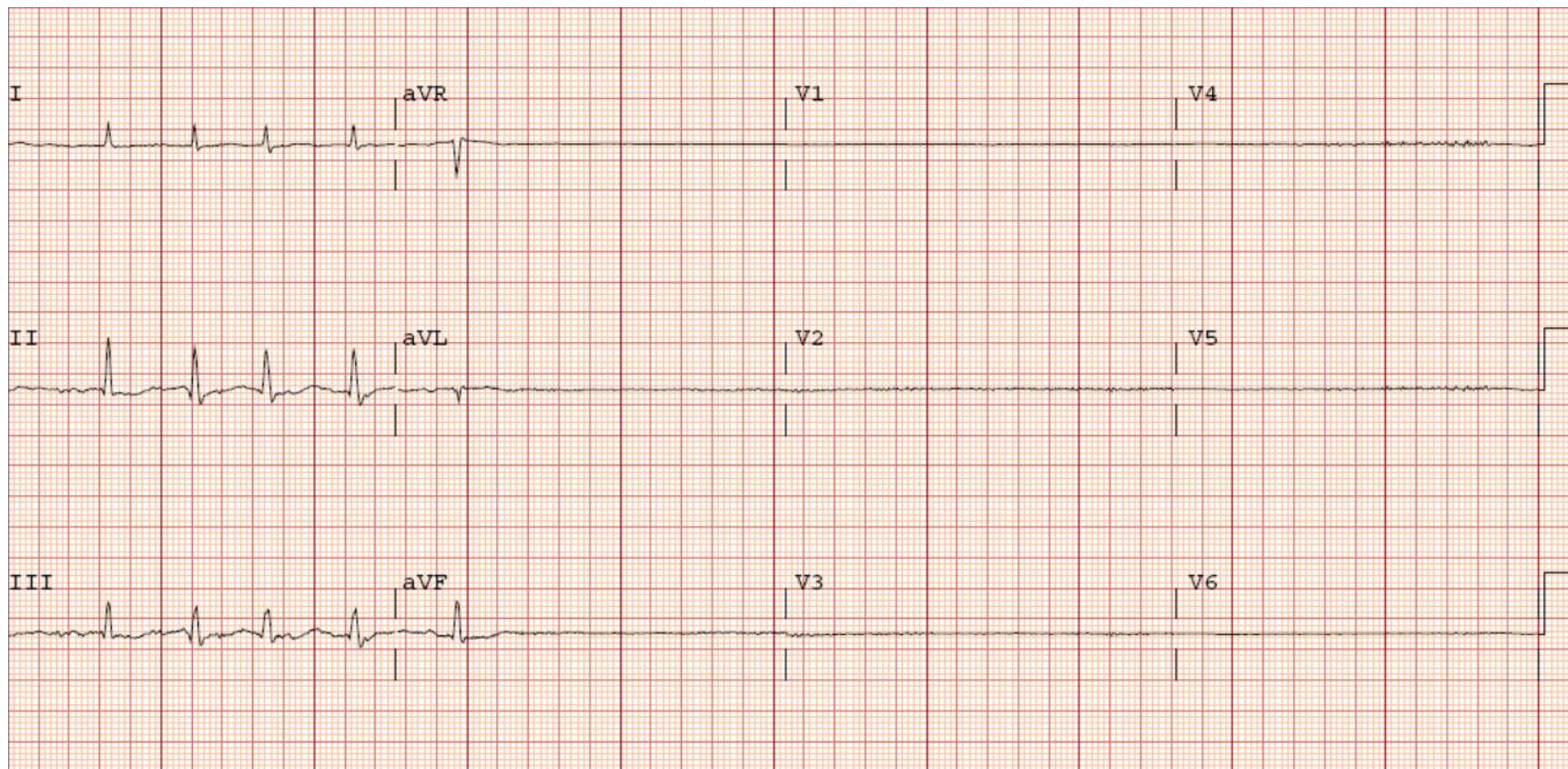
BRADIARRITMIAS

Bradiarritmias

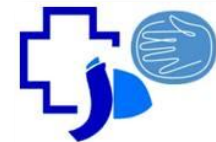


Disfunción sinusal

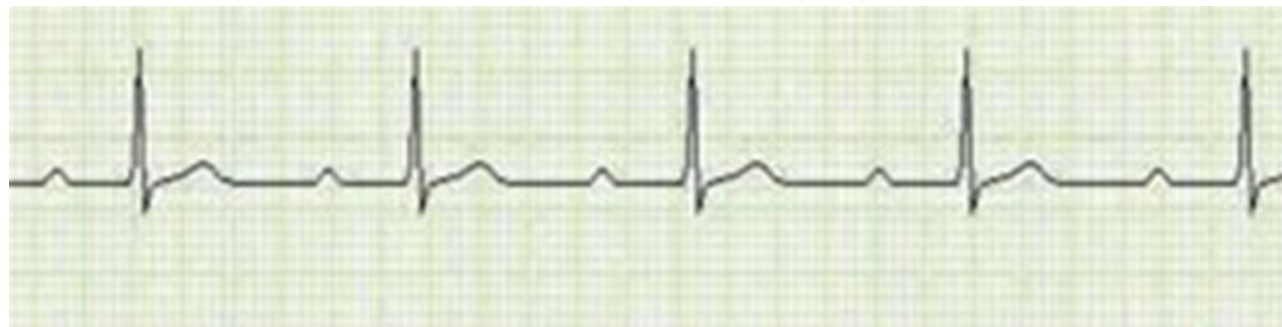
(Bradicardia extrema, Sme bradi-taqui)



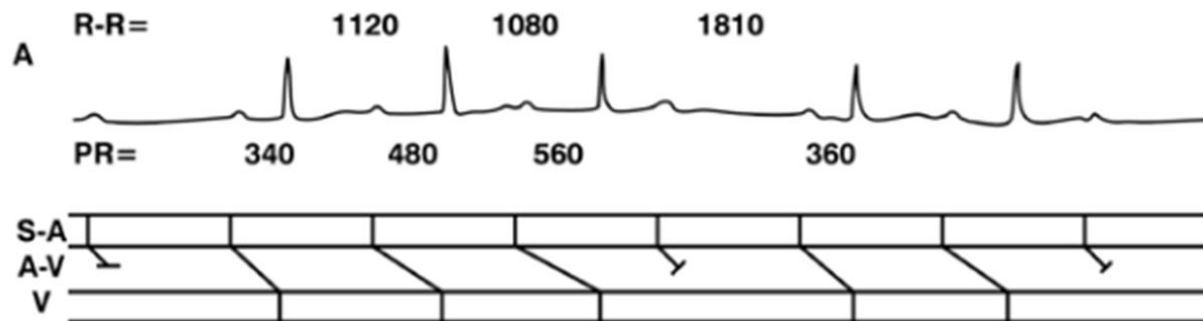
Bradiarritmias



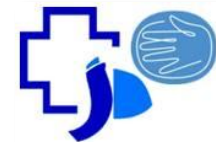
Bloqueo AV 1°



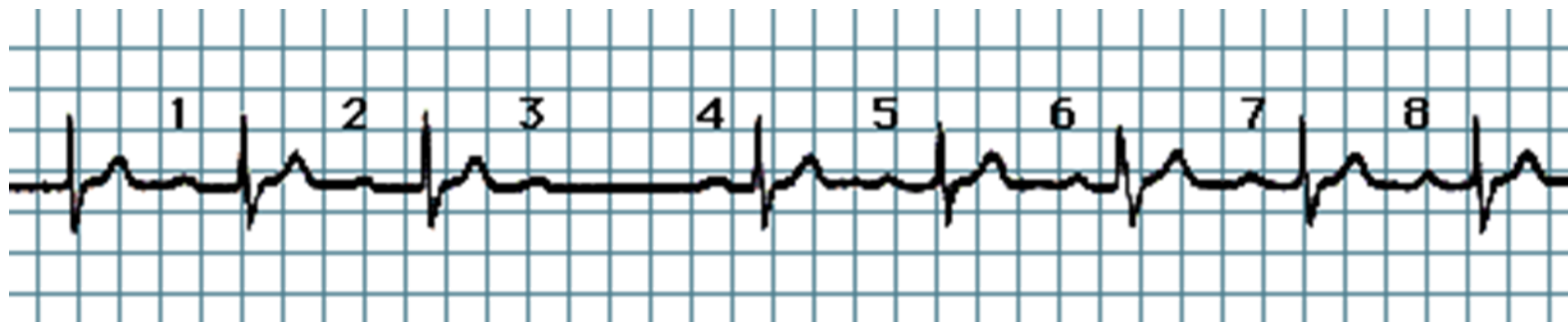
Bloqueo AV 2°
Mobitz 1



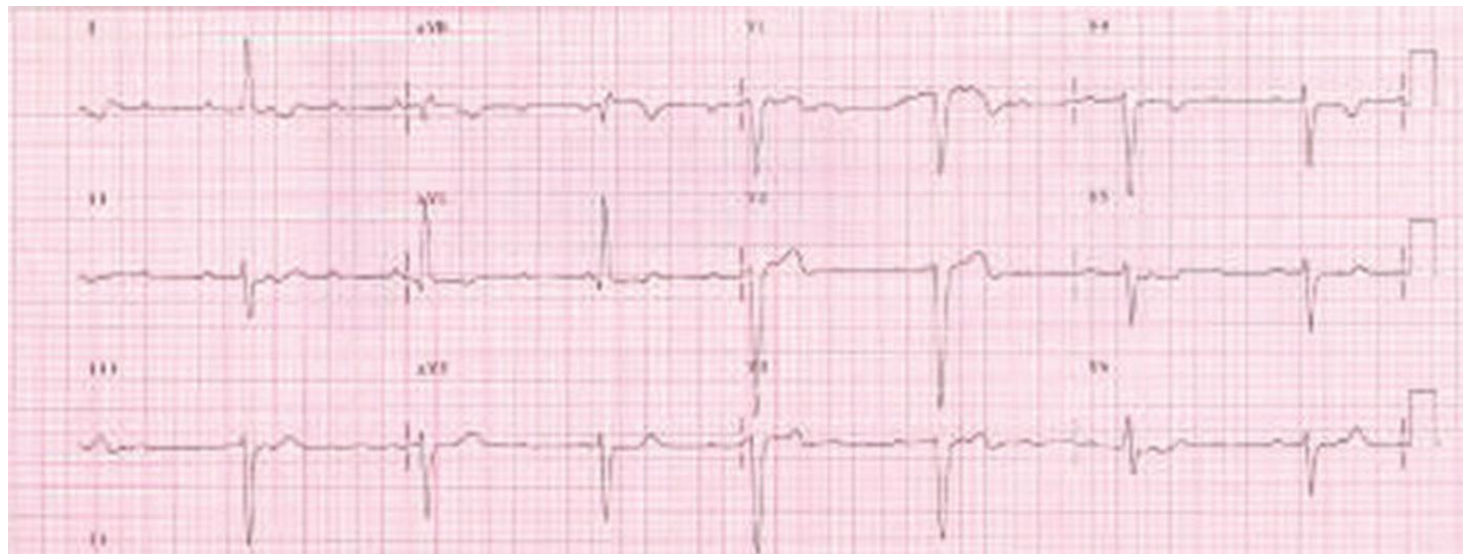Bradiarritmias




Bloqueo AV 2° Mobitz II



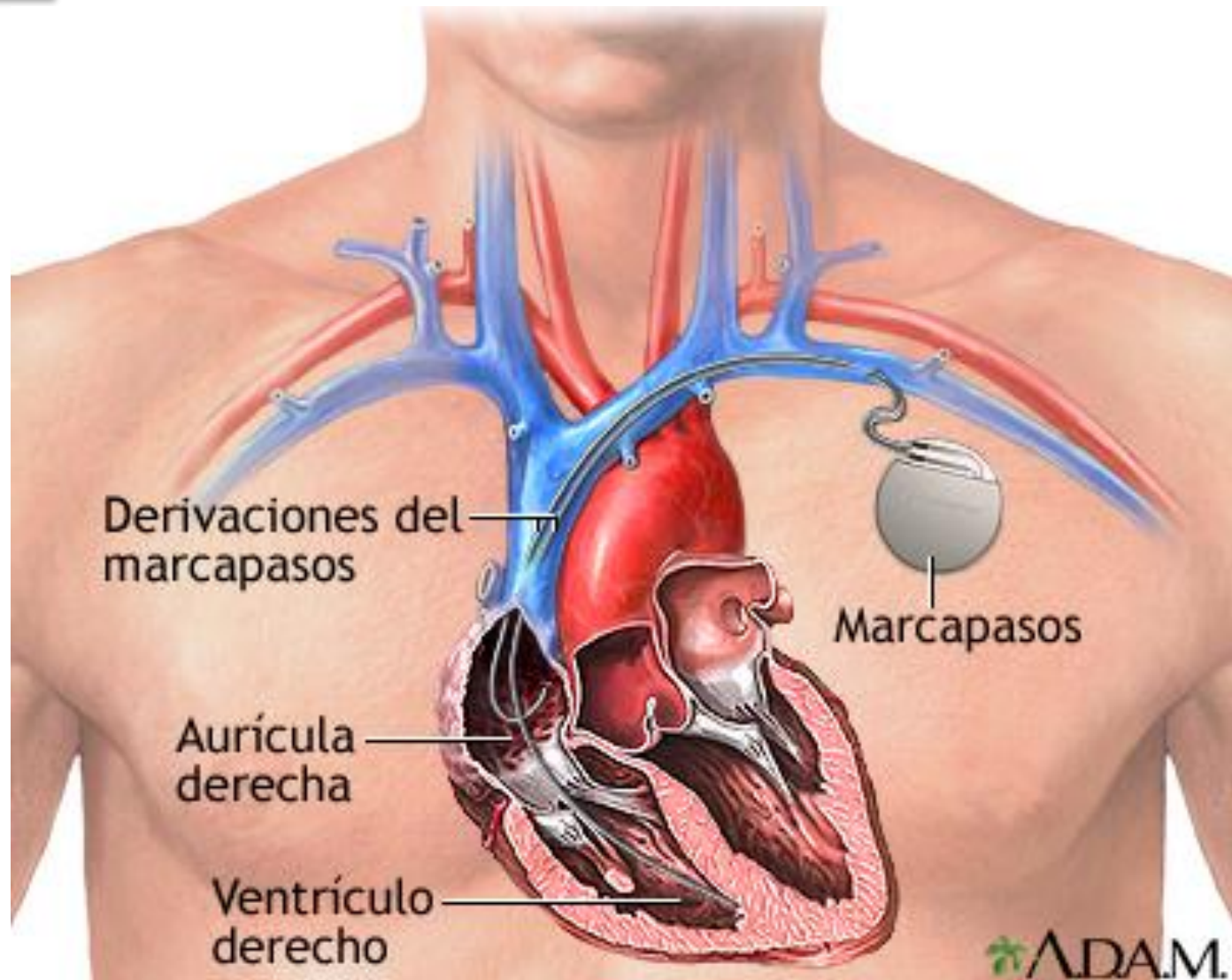
Bloqueo AV 3°




Bradiarritmias



Marcapasos



Bradiarritmias



Marcapasos



Bradiarritmias



Marcapasos



